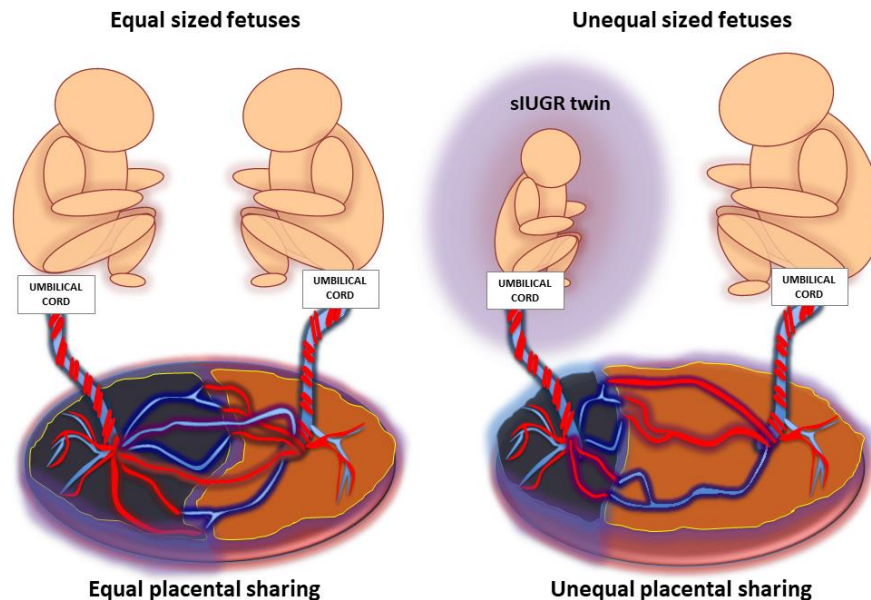


Selective fetal growth restriction

Important things to know

What is selective fetal growth restriction?

Identical, or monozygotic twins obtain their nutrients to grow and develop from a single placenta. In approximately 15% of monozygotic twins the placental supply of nutrients is unevenly shared. When there is unequal placental sharing the fetus that can access the smaller part of the placenta is at risk for intrauterine growth restriction due to nutrient deficiency. In monozygotic twins a size discordance over 25%, or growth delay of one fetus is called selective intrauterine growth restriction or sIUGR.



How does sIUGR harm the babies?

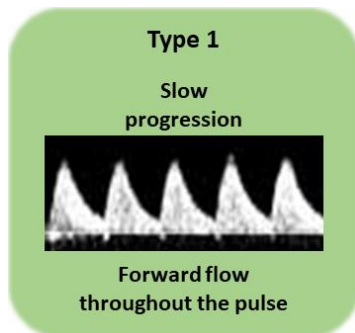
Fetuses that have access to less nutrients because of placental dysfunction are at risk for growth delay and deterioration of well-being. As a result the sIUGR twin is often significantly smaller than the sibling and may require earlier delivery. The degree of growth restriction and the severity of placental function can vary. In mild cases the sIUGR twin is small, but otherwise healthy. In the most severe cases of sIUGR, the baby may not grow large enough to survive and can even be at risk for passing away prior to delivery. The blood vessel connections that exist between all twins in a monozygotic placenta makes deterioration of one twin risky for the co-twin as well. Most dangerous is death of the smaller twin because the larger twin can rapidly lose blood into the demised co-twin. This can lead to severe anemia or even demise of the larger twin. Even if the larger twin recovers from the sudden blood loss and survives there is risk to the brain, heart and kidneys from the severe anemia. Because of these risks, detection of sIUGR and surveillance of both fetuses is important in monozygotic twins.

How is sIUGR detected?

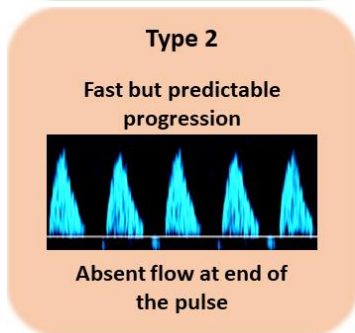
Selective fetal growth restriction is detected by ultrasound measurement of the sizes of both twins. If the size discordance between both babies exceeds 25%, or one baby is smaller than expected for gestational age. Because other complications may co-exist with sIUGR, all monochorionic twins require a detailed ultrasound assessment to exclude the presence of twin-twin transfusion syndrome, or twin anemia polycythemia sequence.

How is the severity of sIUGR determined?

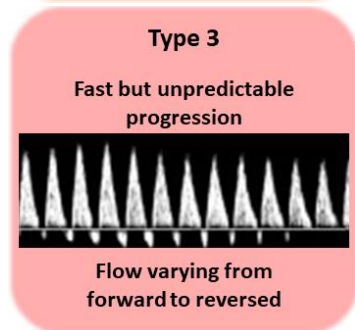
In monochorionic twins with sIUGR, the blood flow pattern in the umbilical artery allows to estimate the likely clinical course and plan surveillance of the pregnancy. Umbilical artery Doppler ultrasound is used to distinguish between three types of sIUGR:



Type 1 sIUGR: This type has the best prognosis. The fetus has forward blood flow in the umbilical artery and is therefore unlikely to become sick or deteriorate early in pregnancy. The small fetus is expected to continue to grow along its own trajectory, remaining small, but otherwise stable. The average gestational age of delivery is 34 to 35 weeks. The risk for unanticipated deterioration of the sIUGR fetus is low.



Type 2 sIUGR: This type is characterized by either persistently absent or reversed blood flow in the umbilical artery of the smaller fetus. Absent or reversed flow in the umbilical artery signifies that the placenta is not functioning normally. Pregnancies complicated by Type 2 sIUGR often require delivery near 30 weeks gestation. Despite a low risk for unpredictable deterioration, frequent fetal monitoring is required in order to determine the optimal gestational age for delivery specific to each pregnancy.



Type 3 sIUGR: Is characterized by a blood flow pattern that fluctuates between heart beats. These patterns often develop during the middle of the pregnancy and can persist for a long time. This finding indicates that there may be a large artery to artery anastomosis between the twins on the placenta, and is associated with the most variable outcomes. Frequent ultrasound is necessary to monitor for deterioration of either fetus which can occur with little warning. The average age for delivery is 32 weeks gestation.

What is the treatment for sIUGR?

The primary management of sIUGR is detailed ultrasound surveillance of the fetal circulations to anticipate fetal deterioration and to select the appropriate threshold in pregnancy when to deliver the babies. Invasive treatments such as selective fetal reduction by cord occlusion can be offered when the sIUGR fetus has a very prognosis placing the other fetus at high risk. Laser surgery is offered when sIUGR co-exists with TTTS or TAPS. Using very strict monitoring and intervention criteria allows for pregnancies to be delivered at the latest gestational age with babies in the best condition possible.