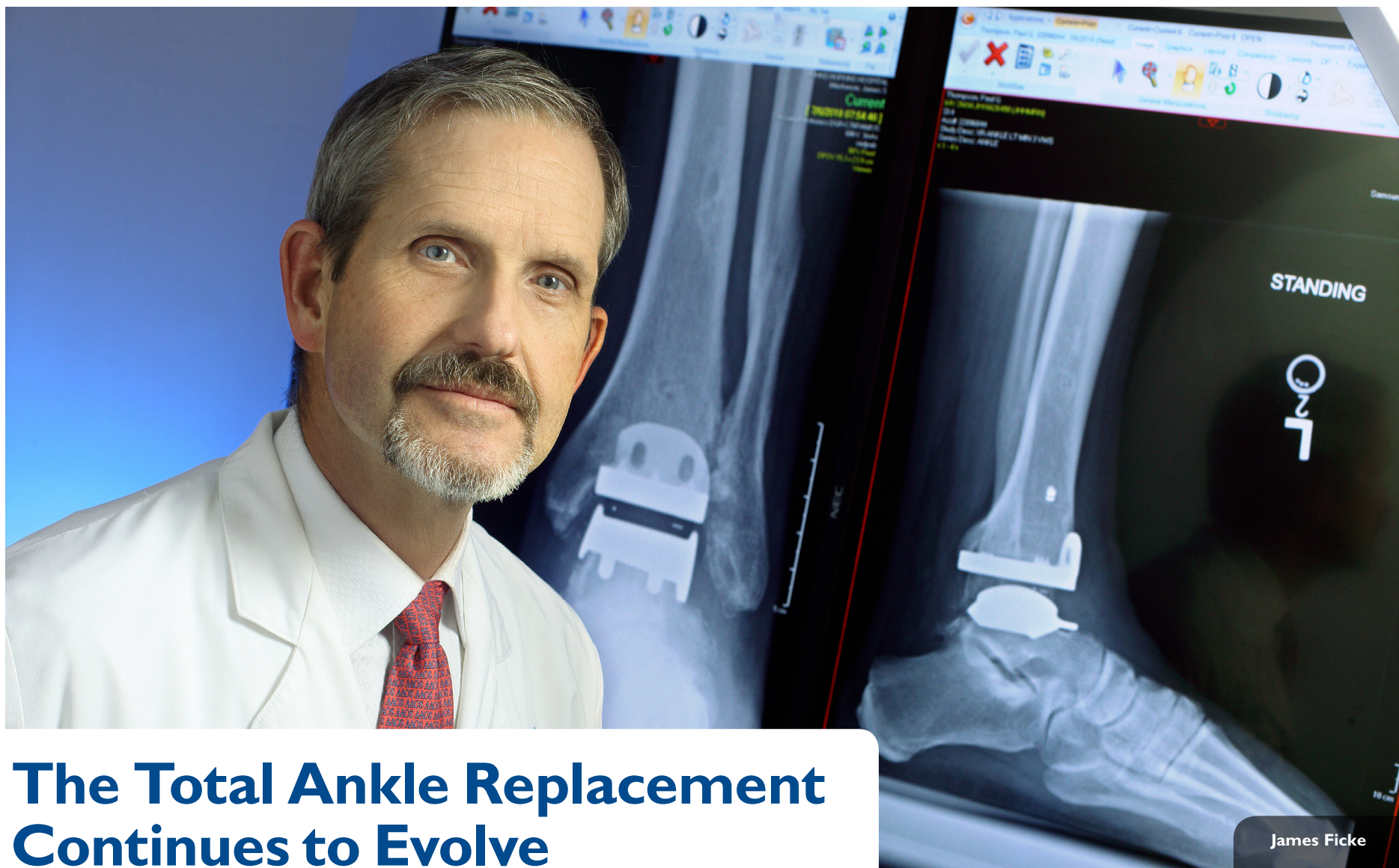



## The Total Ankle Replacement Continues to Evolve

**T**he total ankle prosthesis recently approved by the Food and Drug Administration requires the resection of less bone than other systems now in use in the U.S. “This is an important development because if we do a total ankle replacement with a minimal cut and it fails, there are now other device options for use in revision, without needing to resort to fusion,” says **James Ficke**, professor of orthopaedic surgery at the Johns Hopkins University School of Medicine and director of the Department of Orthopaedic Surgery.

The survivorship of ankle prostheses is roughly 80 percent at eight years, compared with more than 95 percent at 10–15 years for hips and knees. “If you were a patient with ankle arthritis in that 20 percent who failed and you’re 50 years old, you were in a really tough spot because, until recently, there hasn’t been another good option,” says Ficke. “We really need to continue to challenge the designs and surgical techniques in order to improve the survivorship for total ankles.”

Although the typical treatment for late-stage osteoarthritis of the hip or knee is total replacement, that has not been the standard approach for the ankle. For decades, fusion has been considered the best

option, although patients’ recovery can last several months and they must adjust to life with limited joint mobility.

A handful of orthopaedic surgeons in the U.S. are now using the device for total ankle replacement. The Johns Hopkins orthopaedic surgery team implanted its first one in April 2018 and are hopeful that the new device will mean more choices for patients.

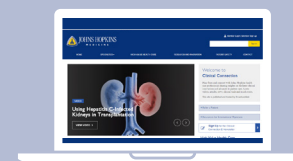**“We really need to continue to challenge the designs and surgical techniques in order to improve the survivorship for total ankles.”**

—James Ficke

The Johns Hopkins team was led by Ficke, who has no financial interest in the newly approved device or any other total ankle prostheses. The team will follow the outcomes of the patients and continue to seek improvements in function for those who suffer from arthritis after injury.

Ficke previously served for three decades in the U.S. Army, and says his interest in ankle treatments springs from his work with soldiers who suffered traumatic foot and ankle injuries.

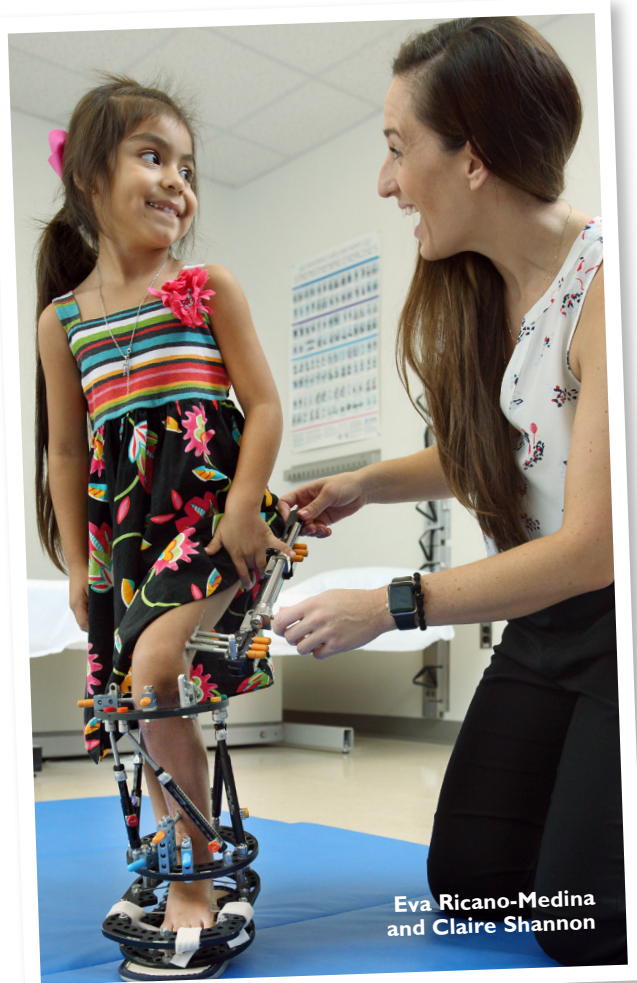“That really led me to my current work on post-traumatic arthritis,” he says. “While people don’t die from arthritis, it does create tremendous disability.” ■



### Explore Our Online Resource for Physicians: Clinical Connection

Connect with Johns Hopkins health care professionals sharing insights on the latest clinical innovations and advances in patient care. Visit [hopkinsmedicine.org/clinicalconnection](http://hopkinsmedicine.org/clinicalconnection)

# Rare Limb Length Differences in Pediatric Patients



Eva Ricano-Medina and Claire Shannon

Limb length differences of under 1.5-2 centimeters are tolerable for most, requiring either no intervention at all or mild fixes such as shoe lifts, says **Claire Shannon**, a Johns Hopkins pediatric orthopaedic surgeon. However, patients with larger differences—which Shannon

can estimate using measurements and algorithms that calculate growth—often require surgical intervention to avoid pain and functional mobility limitations.

When patients come to see Shannon for the first time, she starts by performing a comprehensive physical exam of all the limbs as well as other areas of anatomy that might give a tip-off for undiagnosed genetic syndromes. She also works with colleagues in radiology to collect imaging that can help characterize a patient's deformity.

For smaller limb differences, she often recommends epiphysiodesis to introduce scar tissue in the growth plate of the unaffected limb to halt its growth, allowing the affected limb to catch up as it continues to grow longer. For those with more severe limb differences, she recommends lengthening procedures with an external frame for patients whose growth plates are still active. For those whose growth plates are closed, she recommends an internal rod controlled by magnets.

Each of these lengthening procedures can take up to several months to complete. Patients with congenital deformities often require multiple

**“Every time Eva comes in, she wants to tell me how much straighter and stronger her leg is becoming. It’s great to hear.”**

—Claire Shannon



Physical therapist Alex Parra and Eva Ricano-Medina


procedures every few years as they grow. Close follow-up over time allows Shannon to get to know her patients and families, and to celebrate their successes.

For example, five-year-old Eva Ricano-Medina was born with Ollier's disease, which caused benign cartilaginous tumors at the growth plates in her left leg, bowing the leg and restricting its growth. After a comprehensive physical exam, Shannon used an external frame as part of Eva's treatment.

“When she first met me, she said that all she wanted to do was play soccer. But she just couldn't keep up with the other kids,” says Shannon. Now, “Every time Eva comes in, she wants to tell me how

*(continued on page 4)*

## CUTTING-EDGE RESEARCH

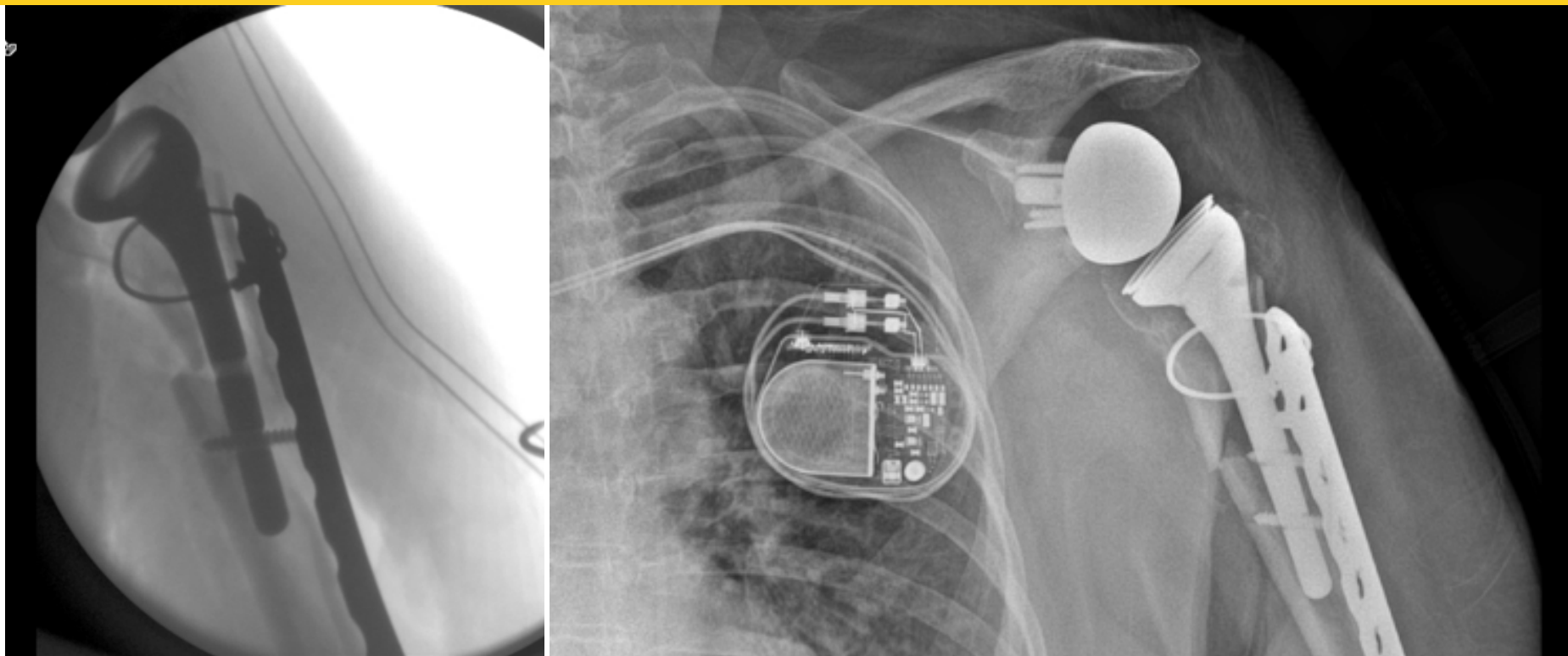


Xu Cao

# Developing New Treatments for Osteoarthritis

Although there are currently no treatments that can modify or halt the course of osteoarthritis in its trajectory, research led by **Xu Cao**, professor of Orthopaedic Surgery at the Johns Hopkins University School of Medicine, may change that.

About five years ago, Cao's team unveiled a new hypothesis about the biology of osteoarthritis and how it first unfolds. Unlike other prevailing views of the disease, which focus primarily on the articular cartilage, Cao's research centered on articular cartilage and subchondral bone as a functional unit, particularly the molecular signals that drive the pathological



## A New Approach for Shoulder Replacements and Fractures in the Midshaft and Below

The X-ray on the left shows a patient's failed shoulder implant. The one on the right shows the revision with the new prosthesis and a plate.

Johns Hopkins orthopaedic surgeons are combining a novel prosthesis for shoulder replacement with a metal plate to make a sturdier repair of fractures in the proximal humerus, midshaft and farther down the humerus.

The prosthesis has a stem with multiple holes along the distal aspect of the shaft, making it possible to connect to the bone with long screws. These holes also enable surgeons to interlock the prosthesis with a plate, offering stronger, more rigid repairs of fractures located below the stem.

While traditionally the shoulder prosthesis is connected to a metal plate using cable and a small screw, “securing the stem and plate with interlocking screws is easier and can be faster than

passing cables,” says orthopaedic surgeon **Uma Srikumaran**. “And it’s definitely stronger with the screws going all the way across the plate, the prosthesis and the bone.”

The absence of cement is another advantage. “If something is off rotationally or out of alignment and you want to make an adjustment, you just remove the screws, make the adjustment and replace the screws,” he says. “It’s a lot faster than having to dig out the cement and start over.”

When there are fractures farther down the humerus, the prosthesis may be a better alternative to press-fit stems, says Srikumaran, mainly because press fitting makes it more difficult for the surgeon to set specific characteristics, such as height and

tension for the reverse shoulder prosthesis.

“This repair allows us to get patients moving sooner because it’s more rigid, which is also an

*(continued on page 4)*

“This repair allows us to get patients moving sooner because it’s more rigid.”

—Uma Srikumaran



changes of the subchondral bone on cartilage. The team showed that by intercepting the signals of the protein called TGF- $\beta$ 1, they could stave off the development of osteoarthritis in mouse models of the disease.

Cao and colleagues, both at Johns Hopkins and at research organizations in China, are now working to translate this discovery into novel therapies for osteoarthritis patients. They are studying two different types of TGF- $\beta$ 1 inhibitors: One is a small molecule inhibitor linked to the osteoporosis drug bisphosphonate, and the other is a chemical analog of a plant-derived compound used in ancient Chinese herbal medicine to treat malaria. The latter inhibitor, known as halofuginone, is now undergoing clinical trial in China to evaluate its safety and efficacy.

The trial, which opened in June, seeks to enroll 40 patients with early stage osteoarthritis of the knee. Participants will receive a single injection of halofuginone into the subchondral bone under

the guidance of an orthopaedic surgeon. This clinical approach is unique among groups currently evaluating potential therapies for osteoarthritis, says Cao. Other investigators typically inject therapeutics into the synovial cavity surrounding the joint. Halofuginone is directly delivered into subchondral bone to inhibit excessively active TGF- $\beta$ 1 and a progression of osteoarthritis.

Participants in Cao’s trial of halofuginone will be followed for one year and monitored both for improvement in joint pain as well as reduction in bone marrow edema in the subchondral bone as visualized by MRI. If successful, the trial in China could enable future trials in the U.S.

“There is no disease-modifying therapy for osteoarthritis, period. So if halofuginone proves safe and effective, it will be the first of its kind,” says Cao. “More broadly, it will also represent a real change in philosophy for how skeletal diseases are treated—addressing both mechanical loading and modulating molecular signals.” ■



### Introducing the Johns Hopkins Doctor Referral App

This new app provides a simple way for health care providers to connect with and refer patients to physicians across Johns Hopkins Medicine in the departments of orthopaedics, surgery, neurosurgery and urology. Registration required.

Visit [bit.ly/hopkinsapp](http://bit.ly/hopkinsapp)

## Rare Limb Length Differences (continued from page 2)

much straighter and stronger her leg is becoming. It's great to hear."

Many length discrepancies stem from congenital or genetic causes, like Eva's; others develop after trauma, such as an injury to the growth plate of a bone. Shannon specializes in correcting limb length discrepancies and is one of a small group of experts in this field nationally and internationally. ■

## A New Approach to Shoulder Replacements (continued from page 3)

advantage because the more rigidity you have," he says, "the easier it is to tension the tightness between the ball and the socket without compromising the fracture fixation."

One recent case highlights the capability of the prosthesis in combination with a plate, Srikumaran says. An 85-year-old woman who fell at home initially had traditional surgery to repair her shoulder. Two weeks later, she felt a pop while at physical therapy, and an X-ray revealed

a failed humeral nail implant. Srikumaran employed the new prosthesis with a plate, and she was able to return to therapy soon after.

"The unique stem allows for flexibility to handle such complex cases," says Srikumaran. "In fact, we're working with the company that makes it to develop even longer stems that would have more holes for additional capabilities." ■

## Your Vital Links

**Johns Hopkins Orthopaedic Surgery**  
Call 443-997-2663 (BONE)  
Visit [hopkinsortho.org](http://hopkinsortho.org)

**Hopkins Access Line (HAL)**  
Your 24/7 connection with Johns Hopkins faculty in any specialty  
Call 410-955-9444 or  
800-765-5447

**Online Referral Directory**  
Find a Johns Hopkins physician by name, specialty and more  
Visit [hopkinsmedicine.org/doctors](http://hopkinsmedicine.org/doctors)

**CME Programs**  
Visit [hopkinscme.edu](http://hopkinscme.edu)  
Call 401-502-9634  
Email [cmenet@jhmi.edu](mailto:cmenet@jhmi.edu)

**Clinical Trials**  
Visit [trials.johnshopkins.edu](http://trials.johnshopkins.edu)

# JOHNS HOPKINS Orthopaedic Surgery

This newsletter is one of the many ways we seek to enhance our partnership with our thousands of referring physicians. Comments, questions and thoughts on topics you would like to see covered in upcoming issues are always welcome. Please email [lrademar@jhmi.edu](mailto:lrademar@jhmi.edu).

*Johns Hopkins Orthopaedic Surgery* is published by Johns Hopkins Medicine Marketing and Communications.

Johns Hopkins Medicine  
Department of Orthopaedic Surgery  
601 N. Caroline St.  
Baltimore, MD 21287

### Orthopaedic Surgery

James Ficke, M.D., F.A.C.S., *Director*  
Thomas Clemens, Ph.D., *Vice Chair for Research*  
A. Jay Khanna, M.D., *Vice Chair for Professional Development*  
Dawn LaPorte, M.D., *Vice Chair for Education*  
Lee Riley, M.D., *Vice Chair for Clinical Operation*

© 2019 The Johns Hopkins University and  
The Johns Hopkins Health System Corporation

### Marketing and Communications

Lisa Rademakers, *Editor*  
Christen Brownlee, Nicole Davis, Lisa Rademakers, *Writers*  
Rachel Sweeney, *Designer*  
Keith Weller, *Photographer*  
For questions or comments, contact:  
Lisa Rademakers at [lrademar@jhmi.edu](mailto:lrademar@jhmi.edu)  
or 443-287-2527.

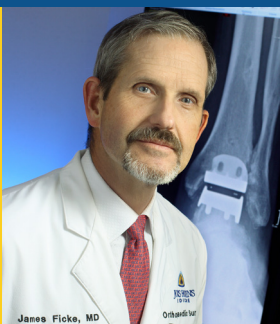Non-Profit Org  
U.S. Postage  
PAID  
Baltimore, MD  
Permit No. 5415



# JOHNS HOPKINS Orthopaedic Surgery

Winter 2019

Inside



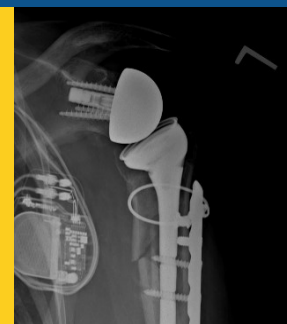
1

The Total Ankle Replacement Continues to Evolve



2

Rare Limb Length Differences in Pediatric Patients



3

A New Approach for Shoulder Replacements and Fractures in the Midshaft and Below

