

Khaled Kebaish shows an approach to spine surgery.

S2-alar-iliac Technique Revolutionizes Spinal Deformity Surgery

While many surgeons do not relish complicated revision surgeries for spinal deformity, **Khaled Kebaish**, director of the Spine Fellowship Program in the Johns Hopkins Department of Orthopaedic Surgery, welcomes the challenge. “I find revision surgery more interesting,” he says. “It’s not routine. There is a lot of planning you have to put into it. You have to think outside the box. Every case is different.”

In one such case, Kebaish performed a patient’s 40th spine surgery. “She had 39 surgeries elsewhere and was referred to us,” he explains. “The main reason she had so many procedures is that they did not achieve good enough fixation in the pelvis. She could have been saved so many surgeries by simply having had this new, simple S2AI technique.”

The revolutionary S2-alar-iliac (S2AI) technique was pioneered by Kebaish and **Paul Sponseller**, director of pediatric orthopaedic surgery at Johns Hopkins. The pelvic fixation technique involves advancing the screw through the ala, thereby providing more purchase across the sacroiliac joint and into the ilium. “Rather than just holding onto the sacrum, you now have a stable anchor in the ilium,” Kebaish explains.

“This technique is more biomechanically stable than the old iliac technique,” says Kebaish. “From start to finish, it is easier. Easy to connect. Easy to teach. It uses only one rod and no connectors. It is a much simpler way to reduce the deformity, correct the deformity, and then connect everything together. Additionally, we reduced the costs by using fewer implants and minimizing operative time.”

Most importantly, complication rates are low with the S2AI technique. In a two-year follow-up study of more than 300 patients, Kebaish and colleagues found that “the revision rate was almost nonexistent, very low, especially revision related to the S2AI or the pelvic fixation, which in some studies was as much as 20 to 30 percent with the previous technique.”

(continued on page 4)

Benefits of S2-alar-iliac (S2AI) technique

- Provides a stable anchor into the ilium.
- Uses only one rod and no connectors.
- Reduces costs with fewer implants and shorter operating time.
- Results in lower complication rates.
- Turns some “hopeless” cases into surgical candidates.



In a two-year follow-up study of more than 300 patients, Kebaish and colleagues found that “the revision rate was almost nonexistent, very low, especially revision related to the S2AI or the pelvic fixation, which in some studies was as much as 20 to 30 percent with the previous technique.”

Better Joint Preservation with Modified Autologous Chondrocyte Implantation

Advancements in joint preservation can make it a viable alternative to arthroplasty for many patients, offering long-term solutions for younger adults and high-demand athletes. **Bashir Zikria**, director of the Johns Hopkins Sports Medicine Arthroscopy Lab, views the restoration of articular cartilage as the keystone of joint preservation.

“Before you do any procedure on the cartilage in the knee, you have to make sure the alignment is correct, the knee is stable and the protective mechanisms are in place,” Zikria says. After observing surgeons in Europe and the Middle East performing osteotomies, Zikria began incorporating that procedure into his practice, along with autologous chondrocyte implantation (ACI),

osteochondral autografts and allografts, complex ligament surgeries, and meniscal transplantation, treating the knee holistically to better protect the cartilage.

“A knee joint’s final endpoint is often a replacement,” says Zikria. “You need to do everything you can before you get to that point.” He finds that ACI is an excellent option for young adults whose knees are often properly aligned. For patients who are 30 to 40 years old, an alignment procedure and meniscal transplantation may be needed, in addition to the ACI.

Zikria’s interest in innovative approaches to joint preservation developed from his own clinical experience. After surgically repairing his patients’ knees, he began finding that five years later, a



Bashir Zikria

certain population of patients developed arthritis. “I thought, I’ve got to do something better than this,” he says. “So I started thinking about better ways to preserve the cartilage.”

A typical ACI procedure involves MRI or CT arthrography to assess the lesion, and then two surgeries. First, surgery is performed to harvest normal articular cartilage, which is cultured in the laboratory. Eight weeks later, a second surgery involves placing a biomembrane patch over the lesion and injecting chondrocytes beneath it. At a cost of approximately \$40,000, it is an expensive treatment.

Through his collaboration with radiologist **Shadpour Demehri**, Zikria is studying whether cells harvested through a small-punch biopsy of articular cartilage during CT arthrography will multiply adequately in vitro to allow enough volume for reimplantation into the affected area of the joint.

The first to try this modified ACI technique, Zikria and Demehri have successfully treated nine patients, reducing the treatment from two surgeries to one, shortening rehabilitative time and decreasing cost.

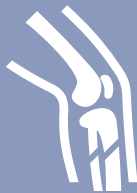The two clinician-researchers are also in the process of creating a Biological Articular

(continued on page 4)

Original procedure

- »MRI or CT arthrography
- »First surgery harvests normal articular cartilage, which is cultured in the laboratory.
- »Second surgery involves placing a biomembrane patch over the lesion and injecting chondrocytes beneath it.
- »\$40,000 cost

ACI procedure comparison



Modified ACI technique

- »Cells harvested through a small-punch biopsy of articular cartilage during CT arthrography will multiply in vitro to allow enough volume for reimplantation into the affected area of the joint.
- »One surgery
- »Shorter rehabilitative time
- »Less cost

DEVELOPING TREATMENTS


Research to Boost Bone Formation Informs Orthopaedic Treatments

For orthopaedic surgery researcher **Mei Wan**, advancing anabolic treatments in osteoporosis and bone fracture repair is the long-term goal of her research on bone marrow mesenchymal stem cells (MSCs). Her core focus is identifying mechanisms that determine the multiple lineage differentiation potential of MSCs, particularly those that give rise to bone-making osteoblasts.

Over the past several years, Wan has made important findings in this area. “We found that the

parathyroid hormone (PTH)—the only FDA-approved drug for osteoporosis—acts on a cell surface co-receptor called LRP6 (low-density lipoprotein receptor-related protein 6),” she explains. “LRP6 is required for MSC osteoblast differentiation and self-renewal.”

Wan is now studying how PTH and LRP6 function in disease conditions such as hyperlipidemia and diabetes, in which there is a high risk of osteoporosis. The



Mei Wan

Expertise Streamlines Care for Hip and Knee Arthroplasty

Far from seeing total joint arthroplasty as a commodity, **Robert Sterling** understands the value of mastery when performing complex hip and knee replacements, and guiding patients through postoperative care and rehabilitation. As a leading Johns Hopkins orthopaedic surgeon, Sterling has lent his expertise to the Johns Hopkins Hip and Knee Program, having performed more than 4,000 arthroplasties in his 15 years of practice. “The more a hospital does of something, the better the outcomes are, and these factors—volume and outcomes—work together synergistically,” he says.

As the department’s vice chair for quality, safety and service, Sterling is focused on the value and quality of the patient experience. “I’m interested in trying to maximize our patient outcomes and minimize the expense on the health care system as a whole,” he says.



Sandy Fenton

Sterling works closely with **Paul Khanuja**, chief of adult reconstruction for hip and knee replacement. Their collaborative research involves analyzing national databases, zeroing in on patients who undergo hip or knee arthroplasty who have other, less common conditions. Their aims are to help surgeons gain a better understanding of the risks these patients face during and after surgery, and to develop ways to reduce those risks.

Sandy Fenton, a travel broadcaster and journalist and former patient of Sterling, has firsthand experience with the exceptional level of care from the Johns Hopkins Hip and Knee Program. Born with hip dysplasia and having undergone multiple corrective surgeries as a child, Fenton understood the importance of quality care. As she reached a point when her chronic hip pain prevented her from traveling, she looked for the best hospital and orthopaedic surgeon to handle her complex hip arthroplasty. Fenton decided on Johns Hopkins and Sterling.

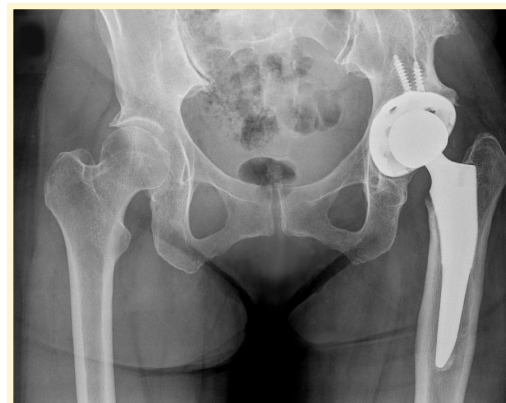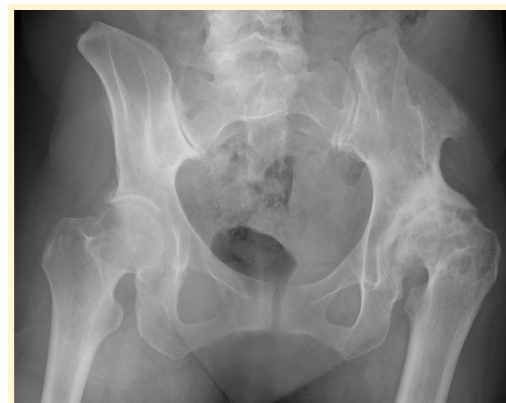“Sandy’s hip was malformed, and the leg was short. She had been highly functional and active despite having a shallow acetabulum and a lateralized femoral head, making her case a particular challenge,” Sterling recalls. Understanding that this would be a life-changing surgery for Fenton, Sterling took into consideration her long-term goals to ensure she was satisfied with her outcomes; namely, walking 3 miles daily.

Sterling’s objective of maximizing patient outcomes goes beyond


expert surgical care. It includes postoperative care tailored to each patient’s needs. “Most of our joint replacement patients are taken care of on the Wenz Orthopaedic Unit,” explains Sterling. “What we have there are physician assistants, nurses and physical therapists who really understand our patients and their unique challenges because they provide dedicated care to them every day.”

In Fenton’s case, this meant engaging in physical therapy in the immediate postoperative period, including assisted walking one day after surgery. When she visited her primary care physician one week after surgery, her scar had healed. Only two weeks after her surgery, she was able to walk a quarter of a mile. Months later, she was walking more than 5 miles on most days.

“I was so pleased with every precaution Hopkins had taken,” says Fenton. “For the first time in my life, I walk straight—not crooked or with a limp. A day doesn’t go by that I am not grateful.” ■



Scans show Sandy Fenton’s hip before and after surgery.



Robert Sterling

importance of Wan’s research is underscored by the prevalence of these conditions. According to recent Centers for Disease Control and Prevention data, approximately 74 million American adults have hypercholesterolemia, and 22 million have diabetes.

Wan has found that oxidized lipids are harmful to bone cells, especially MSCs, because they directly bind to LRP6 and cause endocytosis, which restricts LRP6 from mediating PTH. These findings provide new understanding of the mechanisms by which osteoporosis and hyperlipidemia/atherosclerosis co-develop, and offer an important basis for the future development of new strategies to simultaneously treat both disorders.

Another of Wan’s findings came from a study of animal models treated for coronary artery disease.

After damage to the endothelial layer of the vessels, bone marrow cells mobilized to repair the injury. In this setting, Wan found that “the molecular mechanism is the RhoA inhibitor. RhoA/Rho-associated protein kinase (ROCK) controls the lineage of the MSCs. The cells specifically differentiated into endothelial cells to repair the injury after the treatment of ROCK inhibitor.

“In the bone-related area, that is actually a generalized mechanism,” Wan says. “MSC therapy has been used in preclinical and clinical studies to improve fracture healing, especially for nonunion fracture. In our study, we found that after tissue injury, outside of the bone, the blood level of active transforming growth factor beta (TGF- β) increased substantially, and the bone marrow cells mobilized.

After we blocked TGF- β , the cells just stayed in the bone marrow, rather than mobilizing and repairing the injury.”

Wan credits her colleague, **Xu Cao**, director of the Johns Hopkins Center for Musculoskeletal Research, for inspiring her to pursue this line of research. “He has motivated me because his research is cutting edge in terms of basic research, and then, most importantly, he can translate it into clinical trials to solve real patient problems,” says Wan. ■

S2-alar-iliac Technique Revolutionizes Spinal Deformity Surgery

(continued from page 1)

The Johns Hopkins technique not only makes pelvic fixation easier, but it also turns some “hopeless” cases into surgical candidates. Kebaish describes one such patient. “She had surgery elsewhere, and she was bent over, basically closer to the ground than upright. I did an osteotomy at L5, which you couldn’t do effectively using the old technique. I reshaped the spine and straightened her spine using this technique. Today, I saw her, and she was crying and said, ‘I’m just so happy.’”

“She had been told she wasn’t a candidate for surgery. She came to Johns Hopkins, and we did the surgery. I think that without this technique, we couldn’t have achieved the same outcome,” he says.

With the development of this technique, Kebaish and Sponseller have provided an elegant solution to a highly complex problem. Kebaish has taught surgeons across the country and around the world how best to use the S2AI technique. ■

Better Joint Preservation with Modified Autologous Chondrocyte Implantation

(continued from page 2)

Cartilage Restoration Program at Johns Hopkins that they will co-direct. It will be a multidisciplinary, interventional program that will treat patients with joint degeneration using the latest evidence-backed techniques.

“The true breakthroughs come when you recognize the flaw in a technique and ask how we can do this better,” says Zikria. “We’re always working to improve.” ■

Your Vital Links

Johns Hopkins Orthopaedic Surgery

Call 443-997-9330

Email hopkinsortho@jhmi.edu

Visit hopkinsortho.org

Hopkins Access Line (HAL)

Your 24/7 connection with Johns Hopkins faculty in any specialty

Call 410-955-9444 or

800-765-5447

Online Referral Directory

Find a Johns Hopkins physician by name, specialty and more

Visit hopkinsmedicine.org/doctors

Clinical Trials

Visit trials.johnshopkins.edu

CME Programs

Visit hopkinscme.cloud-cme.com

Call 410-502-9634

Email cmenet@jhmi.edu

JOHNS HOPKINS Orthopaedic Surgery

This newsletter is one of the many ways we seek to enhance our partnership with our thousands of referring physicians. Comments, questions and thoughts on topics you would like to see covered in upcoming issues are always welcome.

Johns Hopkins Orthopaedic Surgery is published by Johns Hopkins Medicine Marketing and Communications.

Johns Hopkins Medicine
Department of Orthopaedic Surgery
601 N. Caroline St.
Baltimore, MD 21287

Orthopaedic Surgery

James Ficke, M.D., F.A.C.S., *Director*

Thomas Clemens, Ph.D., *Vice Chair for Research*

A. Jay Khanna, M.D., *Vice Chair for Professional Development*

Dawn LaPorte, M.D., *Vice Chair for Education*

Lee Riley, M.D., *Vice Chair for Clinical Operation*

Robert Sterling, M.D., *Vice Chair of Quality*

© 2017 The Johns Hopkins University and
The Johns Hopkins Health System Corporation

Marketing and Communications

Dalal Haldeman, Ph.D., M.B.A.,

Senior Vice President

Lisa Rademakers, *Managing Editor*

Rachel Box, *Editor*

Eileen Martin, Jenni Weems, *Writers*

Kristen Caudill, *Designer*

Keith Weller, *Photographer*

Non-Profit Org
U.S. Postage
PAID
Baltimore, MD
Permit No. 5415



JOHNS HOPKINS Orthopaedic Surgery

Winter 2017

Inside



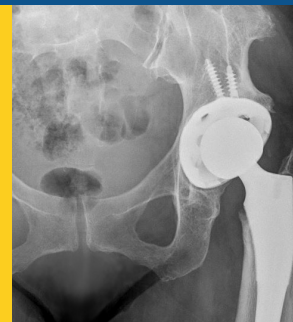1

S2-alar-iliac Technique Revolutionizes Spinal Deformity Surgery



2

Better Joint Preservation with Modified Autologous Chondrocyte Implantation



3

Expertise Streamlines Care for Hip and Knee Arthroplasty

