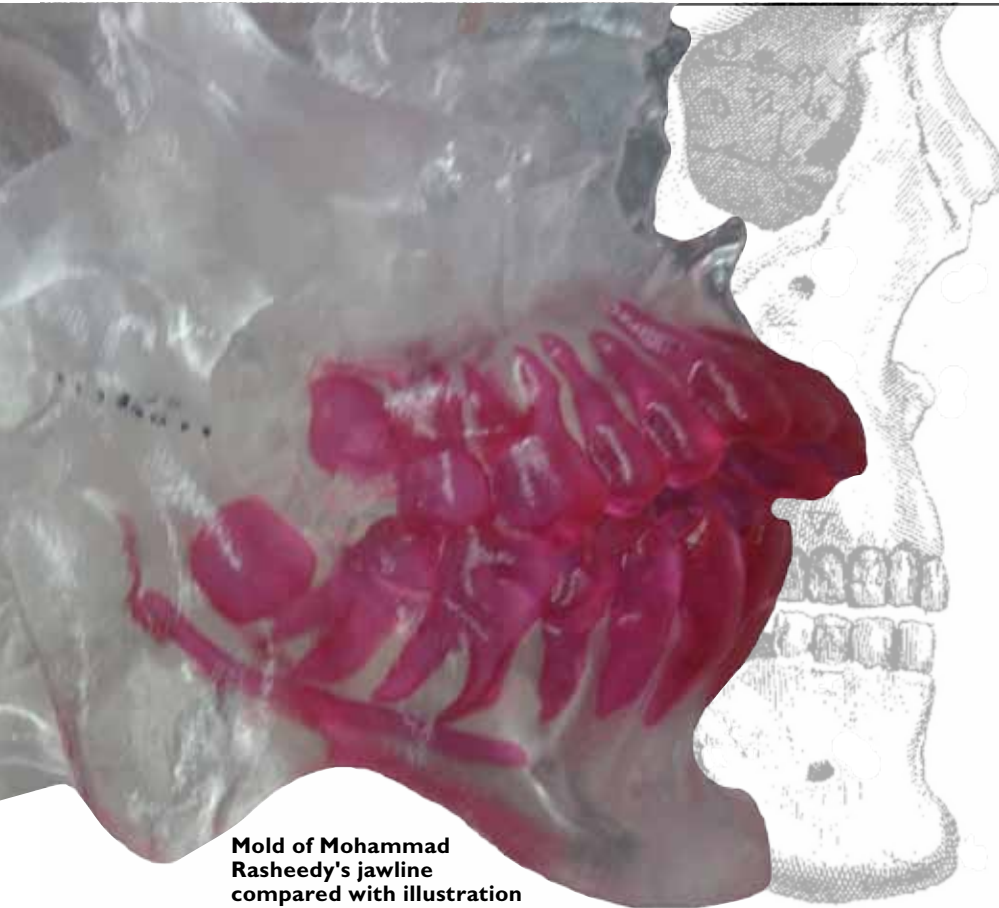


# HeadWay

NEWS FOR PHYSICIANS FROM JOHNS HOPKINS OTOLARYNGOLOGY-HEAD AND NECK SURGERY



Mold of Mohammad Rasheedy's jawline compared with illustration of normal human skull.

## Opening a Mouth, and a Future

**W**hen Mohammad Jawad Rasheedy was an infant, he fell—no one knows exactly how or when—and injured his jaw. His family didn't know the extent of his problem, because he wasn't yet verbal or eating many solid foods, and besides, medical care was scarce in their war-torn hometown of Kabul, Afghanistan.

But as Mohammad grew, it became increasingly clear that he'd taken more than a minor tumble. His lower jaw slowly became locked in place, leaving him unable to open it more than a centimeter. Because of this severe ankylosis, he was restricted to a liquid diet consumed through a straw that poked through teeth that grew outward from the force of his tongue. His limited motion significantly affected his speech, so only his family was able to understand him. He couldn't brush his teeth, leaving them vulnerable to decay.

When he was four years old, a charity organization flew him to Germany for surgery. It only slightly improved his problem. Ten years later, his brother Abdul Hameed, realized that only treatment at one of the world's best hospitals might help Mohammed. Eventually, he reached out to Johns Hopkins, connecting with maxillofacial surgeon **Alexander Pazoki** and director of the division of oral and maxillofacial surgery and dentistry at Johns Hopkins.

"He'd lived so long like this," Pazoki says. "At this point, we had to do what we could to get his mouth open again."

CT scans taken in Afghanistan showed complete ankylosis of the left temporomandibular joint to the glenoid fossa and zygomatic arch and temporal bone, along with an extension of the coronoid process. There was also complete ankylosis of the coronoid process to the zygomatic arch on the right side. After Mohammad and Abdul came to Johns Hopkins in March 2015, Pazoki and his colleagues confirmed this diagnosis with a 3D CT scan, using the collected data to create a stereolithographic model for better evaluation and planning for surgery.

In June, Pazoki, along with facial plastic and reconstructive surgeon **Kofi Boahene** and their colleagues began the four-hour procedure to correct



"KIDS SHOULD BE ABLE TO EAT ICE CREAM AND PIZZA, BRUSH THEIR TEETH AND TELL JOKES. THESE ARE THINGS WE TAKE FOR GRANTED," PAZOKI ADDS. "NOW MOHAMMAD WILL BE ABLE TO ENJOY HIS LIFE."

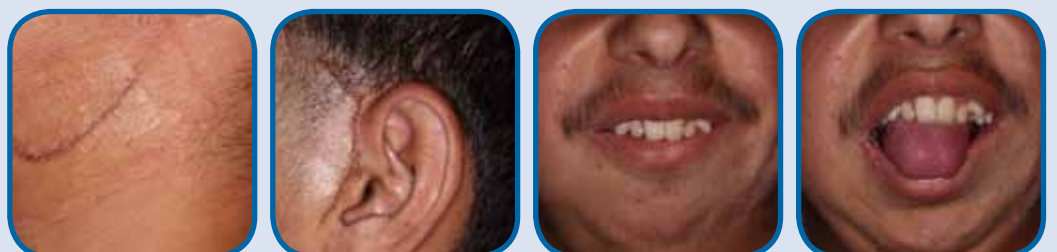—ALEXANDER PAZOKI

*(continued on back page)*

### About the Operation

In a four-hour procedure, Mohammad Rasheedy received a mandibular condylectomy, a bilateral mandibular coronoidectomy and an excision of hyperplastic bony mass on his jaw and temporal bone. To prevent his jaw from fusing shut again, cartilage and skin were taken from his ribcage and grafted onto his temporomandibular joint.

By the next day he was smiling and able to stick his tongue out for the first time in over a decade.



# Less Invasive Surgery for Branchial Cleft Fistulas

**M**any children experience swelling in the neck at some point, often the result of swollen lymph glands from a bacterial or viral infection. Though some patients will have an abscess that requires drainage, when the infection goes away, the swelling usually does as well. But for a rare few, the swelling comes from another source altogether: a branchial cleft fistula.

These openings occur when one or more of the pharyngeal arches—which eventually become cartilage, bone, blood vessels, and muscles—forms abnormally during development, leaving behind a sinus. This anatomical anomaly often goes unnoticed. But eventually, some patients' fistulas become infected, necessitating treatment. However, notes pediatric otolaryngologist **David Tunkel**, many branchial cleft fistulas as a cause of infections often go undiagnosed, even if they recur in the same location.

When a patient has recurring infections in the neck, he says, imaging can reveal the telltale marks of an abnormal sinus. In the past, open surgery to remove the sinus or cyst, or to close off this gap connecting the pharynx and the neck, was the treatment of choice. However, open surgery comes with a host of drawbacks. These fistulas can be associated with important nerves, such as the facial or laryngeal nerve, thus open surgery significantly increases the risk of weakness or even paralysis. Recovery time can include several days with drains in place, a delay before patients can resume a normal diet, and substantial pain. This treatment can also be difficult because of scar tissue left by prior drainage surgery.

Tunkel and colleagues across the country now prefer treating many branchial cleft fistulas with endoscopic surgery, using a laser or cauterization to eliminate these openings. Unlike open surgery, this option is usually an outpatient procedure done by exposing the fistula in the hypopharynx with scopes. By the same night, patients are often home drinking normally with little or no pain medicine.

“Another nice thing about the endoscopic procedure is that you burn no bridges,” Tunkel says. “Because little scar tissue develops, if another infection develops years later, you have the option of performing another endoscopic surgery or open surgery then.”

Tunkel has been offering the endoscopic procedure to patients for 15 years. Although he counsels patients that there's a small chance of recurrence after treatment, he has rarely seen a repeat infection in any of his patients during that time.

“It's extremely gratifying,” he says, “to work at a place where I can offer this level of care.” ■

To refer a patient, call 443-997-6467



“ANOTHER NICE THING ABOUT THE ENDOSCOPIC PROCEDURE IS THAT BECAUSE LITTLE SCAR TISSUE DEVELOPS, IF ANOTHER INFECTION DEVELOPS YEARS LATER, YOU HAVE THE OPTION OF PERFORMING ANOTHER ENDOSCOPIC SURGERY OR OPEN SURGERY THEN.”

—DAVID TUNKEL

## MEET THE TEAM



Shaun Desai, Nicole Schmitt and Wojtek Mydlarz now perform surgeries at Suburban Hospital and The Johns Hopkins Hospital.

## A Growing Department

**T**he Department of Otolaryngology–Head and Neck Surgery continues to grow and is pleased to announce that **Wojtek Mydlarz**, **Shaun Desai** and **Nicole Schmitt** have joined our practice at our Bethesda, Maryland, location. Mydlarz and Schmitt are conducting intramural research at the National Institutes of Health. All three physicians now provide head and neck cancer surgery services in Bethesda, with surgeries to be performed at Suburban Hospital or The Johns Hopkins Hospital.

Mydlarz, an assistant professor in the Division of Head and Neck Cancer Surgery, specializes in the treatment of benign and malignant tumors of the head and neck, including the upper aerodigestive tract, salivary glands, thyroid, skin and soft tissue. His research interests include evaluating both surgical and non-surgical treatment outcomes in head and neck cancer patients.

Desai, an assistant professor in the Division of Facial Plastic and Reconstructive Surgery, offers a broad spectrum of both cosmetic and reconstructive surgery. Reconstructive procedures include facial trauma management, microvascular or “free-flap” reconstruction of major head and neck defects after cancer or trauma, skin cancer reconstruction after Moh's surgery, as well as the management of skin cancer such as malignant melanoma.

Schmitt, an assistant professor in the Division of Head and Neck Cancer Surgery, has clinical interests in surgical treatment and surveillance of patients with benign and malignant tumors of the head and neck, robotic surgery,



# Lip Injections: Beyond Cosmetic Surgery

Each year, thousands of cosmetic surgery patients across the country receive lip augmentation injections with products containing hyaluronic acid. Recent research led by Johns Hopkins facial plastic and reconstructive surgeon **Kofi Boahene** suggests that these injections could serve a purpose far beyond enhancing form—they can also significantly enhance function for people with facial paralysis.

Facial paralysis from tumor, stroke, Bell's palsy, muscular dystrophy, trauma or birth defects can cause both physical and psychological problems, Boahene explains. Without lip control, patients struggle with eating and drinking without spillage, and making sounds that require fully closing the lips, such as words containing the letters "b" and "p." Many individuals with facial paralysis also become self-conscious about how they look.

Boahene says he stumbled across a possible role for hyaluronic acid injection while working with a patient with a then-undiagnosed case of muscular dystrophy. Her face was weak, and she had trouble speaking. To improve her lip muscle tone, he tried the injection and says the effects were immediate. Her face appeared stronger, and her articulation markedly improved.

To see if this procedure might be useful for a wider audience, Boahene and his colleagues recruited 22 patients with facial paralysis on one side of the mouth along with three patients with muscular dystrophy who had lost control of both sides of the mouth.

They performed baseline measures of lip tone by having participants place their lips around an instrument that measured pressure and took readings from the left, middle and right sides of the mouth. The researchers then identified the weakest points by having participants blow air with pursed lips. At points where air escaped, the researchers injected hyaluronic acid.

Results showed the greatest improvement in the three patients with muscular dystrophy, whose lip strength increased six- to seven-fold over the original reading. For participants with paralysis on only one side of the mouth, lip strength increased an average of 1.4-fold on the paralyzed side and 0.4-fold on the unaffected side.

To see how well those improvements carried over to daily life needs, a speech therapist conducted a before-and-after assessment of the patients' ability to speak and to eat and drink without spilling. All 25 patients showed marked improvement, Boahene says. After publishing these results in the June 18, 2015, *JAMA Facial*



**Kofi Boahene says he stumbled across a possible role for hyaluronic acid injection while working with a patient with a then-undiagnosed case of muscular dystrophy.**

*Plastic Surgery*, plans are underway to confirm the benefits in a larger study with about 100 patients.

"To maintain structure, plants fill their leaves and stems with water," Boahene says. "It's a crude analogy, but injecting the lips with hyaluronic acid works in much the same way. It tones the tissue surrounding the muscle."

Boahene says that if the 25 patients continue to show improvement without any marked side effects, he might pursue tests of longer-lasting solutions, such as removing fat from elsewhere in the body and injecting it around the mouth. ■

To refer a patient, call 443-997-6467

benign and malignant thyroid and parathyroid disease, and skin cancers of the head and neck. Her research interests include the use of platinum-based chemotherapy drugs and immunotherapy for the treatment of head and neck cancer.

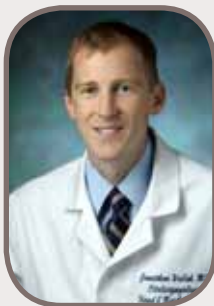**Heather Weinreich, Jonathan Walsh** and **Leah Leinbach** have also joined the department.



**Heather Weinreich**

Weinreich, an assistant professor in the Division of Otolaryngology and Neurotology, focuses on caring for patients with chronic otitis media, cholesteatoma, hearing loss, vertigo and vestibular disorders. Her surgical expertise includes osseointegrated implants, cochlear implants and skull base surgery. She'll be practicing at The Johns

Hopkins Hospital and Johns Hopkins Bayview Medical Center.



**Jonathan Walsh**

Walsh, an assistant professor in the Division of Pediatric Otolaryngology, has clinical interests including head and neck masses, aerodigestive disorders, sinus disease chronic ear disease, hearing loss, sleep apnea, laryngeal cleft, as well as the full spectrum of pediatric head and neck disorders. His research interests are in novel ultrasound technology

applications to head and neck disorders, trans-oral robotic surgery, and airway imaging and modeling. He is practicing at the Johns Hopkins Health Care and Surgery Center in Lutherville, Maryland, and the Johns Hopkins Outpatient Center.



**Leah Leinbach**

Leinbach, an assistant professor in the Division of Oral and Maxillofacial Surgery and Dentistry, has expertise in restorative dentistry, fixed and removable prosthodontics, routine endodontics and oral surgery, and preventative dentistry. Her research interests include oral health considerations for patients receiving radiation/

chemotherapy, the relationship between oral infection and systemic inflammatory processes, and prevention of emergency room visits for dental complaints. She is practicing at the East Baltimore location. ■

To refer a patient, call 443-997-6467

## Opening a Mouth, and a Future *(continued from cover page)*

Mohammad's deformities, including a left mandibular condylectomy, a bilateral mandibular coronoidectomy, and an excision of a hyperplastic bony mass on his jaw and temporal bone. To prevent his jaw from fusing shut again, they also grafted cartilage and skin taken from his ribcage onto his temporomandibular joint.

Upon awakening from anesthesia, Mohammad was scared, Abdul remembers; he worried that the numbness in his lips and tongue were permanent. But the next day, after the anesthesia completely wore off, he was smiling and sticking his tongue out—for the first time in over a decade. He has continued to improve with physical therapy

over the past few months, Pazoki says, eating a soft diet and relearning how to speak.

Though Mohammad still has a long way to go, with further surgery slated after he's finished growing to perform a complete bilateral joint reconstruction, he's come a long way in just a few short months, Pazoki says.

"Kids should be able to eat ice cream and pizza, brush their teeth and tell jokes. These are things we take for granted," Pazoki adds. "Now Mohammad will be able to enjoy his life." ■

For information: 443-997-6467

## Explore Our Online Resource for Physicians: **Clinical Connection**

Connect with Johns Hopkins health care professionals sharing insights on the latest clinical innovations and advances in patient care.



Scan the QR code or visit [www.hopkinsmedicine.org/clinicalconnection](http://www.hopkinsmedicine.org/clinicalconnection).

While you're there, sign up for the Clinical Connection e-newsletter.

# HeadWay

Johns Hopkins Medicine  
901 S. Bond St., Suite 550  
Baltimore, Maryland 21231

This newsletter is published for the Department of Otolaryngology–Head and Neck Surgery by Johns Hopkins Medicine Marketing and Communications.

#### Department of Otolaryngology–Head and Neck Surgery

David W. Eisele, M.D., F.A.C.S., Andelot Professor and Director

#### Marketing and Communications

Dalal Haldeman, Ph.D., M.B.A., senior vice president  
Justin Kovalsky, managing editor  
Christen Brownlee, writer  
Lori Kirkpatrick, designer  
Keith Weller, photographer

For questions or comments, contact:  
mayd@jhmi.edu or 410-955-2902

© 2015 The Johns Hopkins University and  
The Johns Hopkins Health System Corporation.

Non-Profit Org  
U.S. Postage  
PAID  
Permit No. 5415  
Baltimore, MD

# HeadWay

NEWS FOR PHYSICIANS FROM JOHNS HOPKINS  
OTOLARYNGOLOGY–HEAD AND NECK SURGERY



Inside



1

Opening a Mouth, and a Future



2

Less Invasive Surgery for Branchial Cleft Fistulas



3

Lip Injections: Beyond Cosmetic Surgery