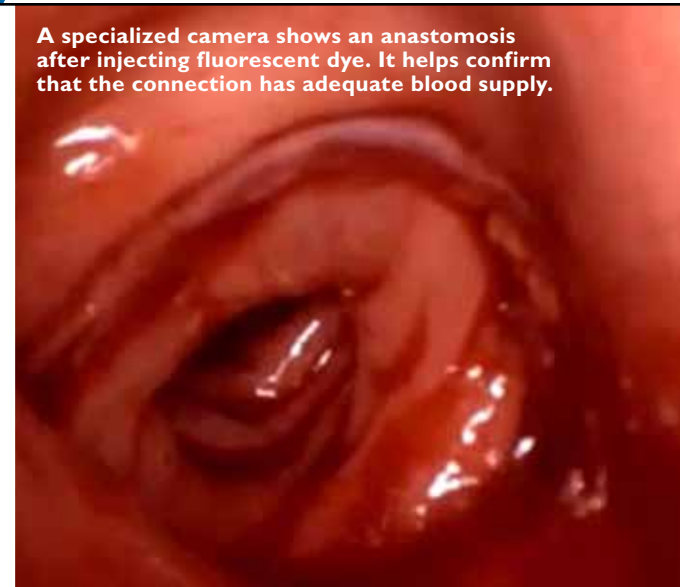
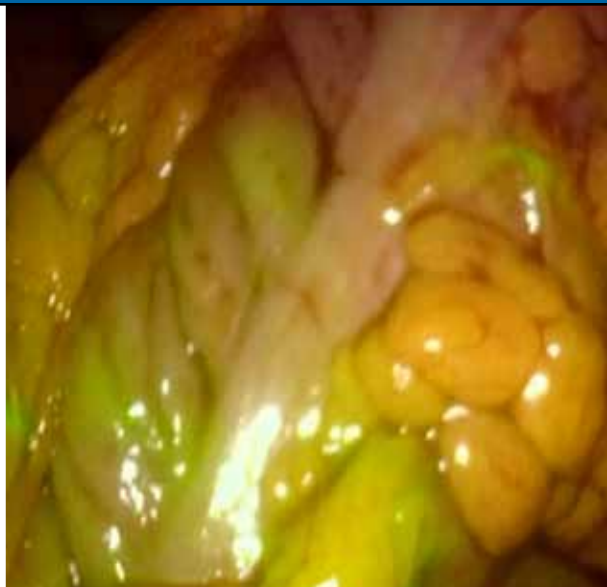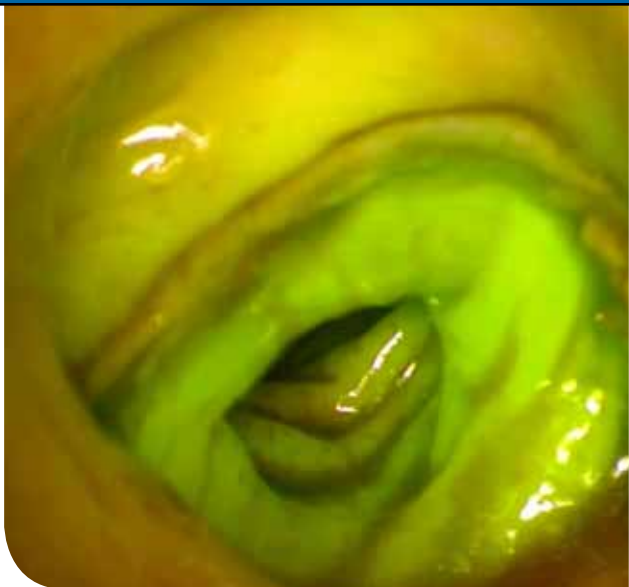


# JOHNS HOPKINS Surgery

SUMMER 2015



NEWS FROM THE JOHNS HOPKINS  
DEPARTMENT OF SURGERY



A specialized camera shows an anastomosis after injecting fluorescent dye. It helps confirm that the connection has adequate blood supply.

## Proctectomy and Anastomosis for Low Rectal Cancer

**W**HEN A BUSINESS EXECUTIVE WAS diagnosed with a cancerous tumor just 3 centimeters away from his anus, he was told that his only option was a colostomy. He sought a second opinion, however, from surgeon **Bashar Safar** at The Johns Hopkins Hospital, where he would ultimately undergo treatment—thousands of miles from his home in China.

“The majority of my low rectal cancer surgeries don’t result in colostomy,” says Safar. The key, he says, is in the way that the cancer is removed. Frequently, Safar uses a surgical robot for a proctectomy and stoma-sparing anal anastomosis. “It’s a confined space, and access is difficult. When you go really low in the pelvis,” he says, “it’s hard to see and get a clean surgery plane, but the robot can facilitate this approach to rectal dissection.”

Ports in the abdomen provide access for the robot’s instruments to the rectum. A camera on one of the instruments allows a clear view of the pelvic structures and planes so Safar can decide precisely where to cut. The goal, he says, is a complete excision of the rectum and surrounding tissue; the

specimen is removed in one piece without cutting into it or nearby tissue or bone. “If the operation is compromised,” he says, “the disease can come back again.”

Surgery for the recurrent cases can be particularly challenging due to scar tissue that obscures the normal anatomical landmarks. For these and more advanced cancers, Safar mobilizes a team from multiple disciplines, including urology, gynecology, plastic surgery and radiation oncology. The urologist can reconstruct the urinary system or remove the bladder or prostate if needed. A gynecologist can perform a hysterectomy if needed and a plastic surgeon can reconstruct the pelvis.

When the margins are close to tissue or the pelvic bones, Safar works with radiation oncologists to deliver intraoperative radiation to the area for about an hour, which can help reduce the risk of disease recurrence.

Thanks to Safar’s extensive experience with cancer that occurs low in the rectum, he was able to remove the executive’s cancer without a colostomy. “We do a lot of these procedures,” says Safar, “and we get good results.” ■

To refer a patient: 443-997-1508



To see a video on treatment options for rectal cancer, please visit [http://bit.ly/rectal\\_cancer\\_treatments](http://bit.ly/rectal_cancer_treatments).

### Testing Fluorescence Imaging to Avoid Anastomotic Leaks

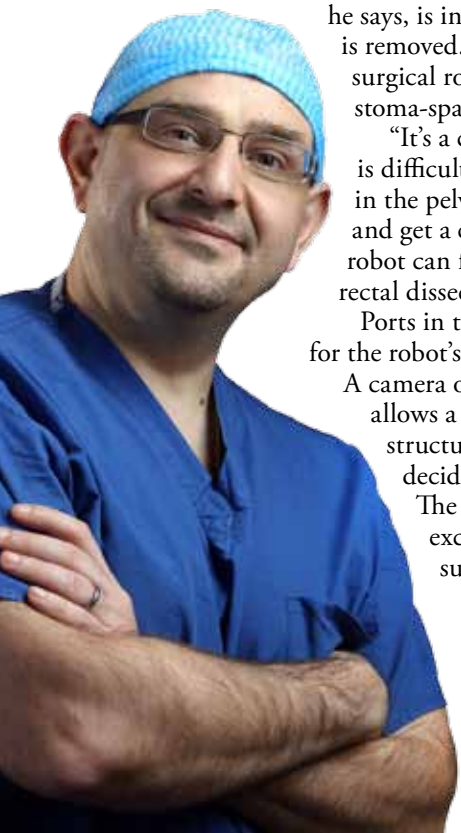
Colorectal surgeons use their best judgment when performing an anastomosis. If the tissue is dark in color, they stay away. If it is pinker, they proceed. Looking for a better way to identify healthy tissue, Bashar Safar is taking part in a clinical trial using fluorescence imaging to reveal blood flow.

During a low anterior resection, Safar will inject a fluorescent dye and then use a special camera to see where the tissue lights up. Within seconds, the area with healthy blood flow brightens. After surgery, he will follow the patients to see if they experience any anastomotic leaks.

“If this can tell us that an anastomosis is going to be fine, we could avoid the temporary stoma that some patients have,” says Safar. “It could potentially augment clinical decision-making.”

“THE MAJORITY OF MY LOW RECTAL CANCER SURGERIES DON’T RESULT IN COLOSTOMY. THE KEY IS IN THE WAY THAT THE CANCER IS REMOVED.”

— BASHAR SAFAR



# A Delicate Situation: Marfan, Loeys-Dietz Syndromes and Hernia Repair



**H**ERNIA PATIENTS WITH connective tissue disorders, like Marfan syndrome or Loeys-Dietz syndrome, are in a delicate situation, because their tissues tend to be weak, and their bodies typically heal slowly. “This group doesn’t do as well with the same procedures we offer everyone for hernias,” says acute care surgeon **David Efron**. “Even though they make scar tissue that looks good, it doesn’t hold very well.”

Efron gained significant knowledge about connective tissue disorders when Johns Hopkins researcher **Harry Dietz** started referring his patients to Efron for surgery. Dietz is recognized as the world’s authority on Marfan syndrome; he and his colleagues described the related Loeys-Dietz syndrome for the first time in 2005.

Before this distinction, patients with Loeys-Dietz were often misdiagnosed with Marfan. While both disorders primarily affect the cardiovascular and skeletal systems, patients with Loeys-Dietz do not have ocular lens dislocation issues like patients with Marfan syndrome.

The most serious symptom associated with both disorders is the weakening and widening of the aorta, which can lead to an enlarged aortic root and requires surgery to replace. Both syndromes also typically cause heart murmurs and leaky mitral valves that need to be replaced.

After cardiac or other surgery in this population, hernias often occur because the surgical incisions do not heal as well. In fact, nearly all patients with Loeys-Dietz have recurrent hernias as well as easy bleeding, bruising and scarring problems.

At the Johns Hopkins Institute of Genetic Medicine’s Connective Tissue Disorder Clinic, these patients receive care and therapy from Dietz and others. When someone has a hernia in the abdomen, groin or diaphragm, Efron is the go-to surgeon.

Over the years, he has refined his approach for optimal repair in patients with connective tissue disorders. For example, whenever possible, he has patients stay on their medications for stabilizing connective tissue. In particular, patients with Loeys-Dietz remain on losartan throughout surgery or resume taking the drug as soon as possible after the procedure.

Because he finds patients with Loeys-Dietz often have an exaggerated immune response, Efron also ensures they have steroids or other medications to control inflammation before the operation. He prefers to make the repair in a setting where an emergency response can take place if needed, rather than in an outpatient setting.

Typically, Efron says, a standard single mesh approach does not suffice in these patients, because the tissue doesn’t hold. Instead, he uses a biological material from below the hernia and a plastic mesh on top to create a buttress from above and below. The materials are then secured through the abdominal wall.

“I’m cognizant of a potential weak spot in these patients more than in others,” he says. “It impacts my surgical decision-making and technique.” ■

“THIS GROUP DOESN’T DO AS WELL WITH THE SAME PROCEDURES WE OFFER EVERYONE FOR HERNIAS. EVEN THOUGH THEY MAKE SCAR TISSUE THAT LOOKS GOOD, IT DOESN’T HOLD VERY WELL.”

—DAVID EFRON

To refer a patient: [443-997-1508](tel:443-997-1508)

## HEPATOBIILIARY DISEASES

# Expanding Options for Liver Transplant Patients

**L**IVER TRANSPLANT CANDIDATES OF patients with liver and biliary diseases in the Washington, D.C., area who want to be treated at The Johns Hopkins Hospital but don’t want to travel to Baltimore now have new, viable options.

The hospital’s liver team now offers medical care at Sibley Memorial Hospital in Washington, D.C., Suburban Hospital in Bethesda, Maryland, and at three outpatient clinics in the D.C. region.

“The goal,” says Clinical Chief of Transplantation **Benjamin Philosophe**, “is to provide world-class treatments with an academic approach for our liver patients throughout the system.”

All of the services provided at the Comprehensive Transplant Center at The Johns Hopkins Hospital—except for the actual surgery—are offered at the regional sites. Patients can receive therapies for advanced liver disease and liver tumors, get clinical evaluation and lab work and review of pathological

and radiologic studies, undergo evaluation for organ transplantation, access clinical trials for chronic liver disease and liver transplantation, and receive follow-up care after procedures.

The transplant hepatologists at the facilities are all full-time Johns Hopkins faculty. Some work primarily at The Johns Hopkins Hospital in Baltimore and rotate to see patients in the other locations, while others primarily treat patients in the D.C. region and see patients in Baltimore.

With full teams of interventional radiologists, medical oncologists, and transplant and hepatobiliary surgeons, as well as nurse navigators to help facilitate communication between sites, “the partners in our system now manage the complex care of liver patients just as we always have at The Johns Hopkins Hospital,” says Philosophe. ■

To refer a patient: [410-614-2989](tel:410-614-2989)



**Benjamin Philosophe, left, and Robert Montgomery** head an initiative to provide Johns Hopkins liver transplant care in the Washington, D.C., region.

ACCORDING TO THE LATEST SCIENTIFIC REGISTRY OF TRANSPLANT RECIPIENTS REPORT, **THE ONE-YEAR PATIENT SURVIVAL RATE AFTER A LIVER TRANSPLANT AT THE JOHNS HOPKINS HOSPITAL IS THE HIGHEST IN THE REGION: 94.1 PERCENT.**

NATIONAL AVERAGE: 90.8 PERCENT.

# Two Aesthetic Approaches When Breast Cancer Tumors Are Small

**W**HEN WILLIAM HALSTED devised the first procedure to remove breast cancer more than 100 years ago, it was a radical approach in search of a cure. He removed tissue, muscle and lymph nodes. Today, Halsted's spirit inspires surgeons at The Johns Hopkins Hospital who continue to remove breast cancer successfully, but with vastly more conservative and advanced approaches.

Thanks to digital tomosynthesis imaging, for example, breast surgical oncologist **Mehran Habibi** gets highly focused three-dimensional pictures of any disease in the breasts. "It produces hundreds of images, and I can see the size and placement of the lesions more clearly," he says.

Habibi then consults with medical and radiation oncologists to determine whether neoadjuvant chemotherapy could be beneficial. Whenever the tumor is small enough and far enough away from the nipple and areola, he can offer a nipple-sparing mastectomy to preserve the skin, nipple and areola.

The incision for the procedure goes under the breast and creates a long skin flap. In most cases,

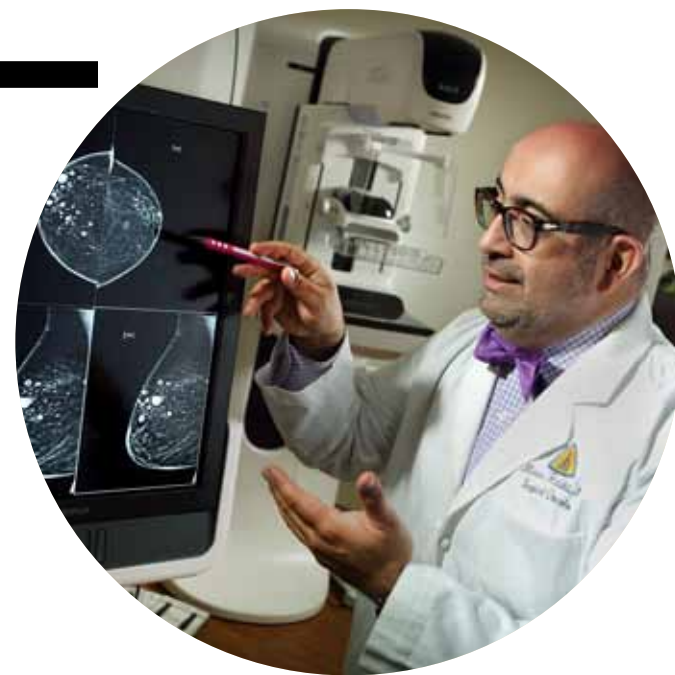implants are used in place of the removed breast tissue, but for patients who do not want implants or have had radiation, the team can use abdominal tissue and perform microanastomosis to connect the blood vessels between the abdomen and chest tissue.

Over the last eight years, Habibi has had no instances of local cancer recurrence or nipple necrosis after a nipple-sparing mastectomy. The key to success, he says, is the thickness of the flap. "If it is too thick, the possibility of disease entering the flap goes up," he says. "If it's too thin, the potential for skin and nipple necrosis goes up."

Habibi performs the procedure not only for patients with small tumors, but for patients who have an increased risk of developing cancer due to the BRCA2 gene. "We are able to reduce their risk by more than 90 percent with the surgery, and cosmetically it looks as if they had never had an operation," he says.

Another option for patients with small tumors who are also candidates for breast reduction surgery is the oncoplastic lumpectomy. Working with a plastic surgeon, Habibi combines a lumpectomy with breast reduction. "We design the reduction to be in the same area as the lumpectomy and reduce both breasts," he says.

*(continued on back page)*



**Mehran Habibi reviews digital tomosynthesis images for the size and placement of lesions in breast tissue.**

## MEHRAN HABIBI'S PROCEDURES: BY THE NUMBERS

**250+ per year**  
CANCER, PRECANCER AND  
BENIGN DISEASE OPERATIONS



"ANY BREAST CANCER SURGERY OUGHT TO BE DONE WITH ONCOPLASTIC PRINCIPLES IN MIND."

— LISA JACOBS



**Among the patients with TOS whom Ying Wei Lum has treated are hockey players, musicians, swimmers, baseball players and hairstylists.**

# Thoracic Outlet Syndrome Diagnosis and Treatment: A Johns Hopkins Mainstay

**T**HORACIC OUTLET SYNDROME (TOS) can be a bear to diagnose, but once it is, says vascular surgeon **Ying Wei Lum**, "we're able to help a good 90 percent of our patients."

Lum leads a team of providers who know this condition unusually well. Patients come from across the country, because Johns Hopkins is one of the few hospitals where TOS is diagnosed and treated. Why? "Thoracic outlet syndrome is rare, and diagnosis is hard," Lum says. "No single test pinpoints the condition." The Johns Hopkins team performs between 60 and 80 operations each year to reduce the TOS-causing problem: compression on the brachial plexus, subclavian artery or subclavian vein.

Anyone whose activities involve regular shoulder flexion and abduction and an elbow perched at shoulder height or higher is at risk for TOS. Other causes may be physical trauma, anatomic anomalies like a cervical rib, scalene muscle anomalies, tumors and even poor posture.

The vast majority of cases are injury-related and involve pressure from a scalene muscle, a supernumerary cervical rib or both on nerve roots of the brachial plexus.

"This neurogenic type of TOS can go on for a long time and cause pain and even muscle atrophy,"

says Lum. "But TOS involving the subclavian vein or subclavian artery should be treated more urgently."

Compression of the subclavian vein can lead to thrombosis, a swollen arm, bluish color of the hand and fingers, and pain. It is usually managed initially with or without thrombolysis, followed by anticoagulation therapy. Surgery should be considered to prevent recurrent thrombosis. Arterial TOS, the least common and most urgent of the three conditions, poses a risk for subclavian aneurysms and a thromboembolic event that could lead to an ischemic arm.

Lum and his associates are researching ways to improve more accurate detection of TOS and prompt referral. He is also interested in research to determine patient selection to yield the best functional outcomes.

Recent research supports completely removing the first rib to prevent recurrence of symptoms in neurogenic TOS.

"We're on solid footing to improve outcomes for even more patients," says Lum. ■

To refer a patient: 410-955-5165

## Two Aesthetic Approaches

(continued from page 3)

“These patients have natural-looking breasts that age with them,” says breast surgeon **Lisa Jacobs**. “It’s a part of their body versus an artificial implant that gets replaced in 10 or 15 years. These days, any breast cancer surgery ought to be done with oncoplastic principles in mind.”

The procedure itself involves an incision around the nipple and areola, a vertical incision from the nipple to the lower area of the breast, and a horizontal incision in the fold of the breast. Habibi sees clear margins in 90 percent of cases as well as aesthetic cosmetic outcomes. ■

To refer a patient: 443-997-8282

## Johns Hopkins Surgery Referral Line

Call **443-997-1508** to refer a patient  
Easy access and quick appointments for your patients at these convenient locations:

**Green Spring Station**  
**White Marsh**  
**Johns Hopkins Bayview Medical Center**  
**The Johns Hopkins Hospital**

Our schedulers are available to assist you Monday through Friday, 8 a.m. to 5 p.m. For after-hours or emergency transfers, please use the **Hopkins Access Line** at 410-955-9444.

## Explore Our New Online Resource for Physicians: **Clinical Connection**



Connect with Johns Hopkins health care professionals about the latest clinical innovations and advances in patient care. Access videos, articles, news, clinical trials and much more.

Scan the QR code or visit [www.hopkinsmedicine.org/clinicalconnection](http://www.hopkinsmedicine.org/clinicalconnection).

# JOHNS HOPKINS Surgery

Johns Hopkins Medicine  
901 S. Bond St., Suite 550  
Baltimore, Maryland 21231

This newsletter is published for the Department of Surgery by Johns Hopkins Medicine Marketing and Communications.

### Department of Surgery

Jonathan Efron, *interim director of the Department of Surgery*

### Marketing and Communications

Dalal Haldeman, Ph.D., M.B.A., *senior vice president*  
Justin Kovalsky, *editor*  
Karen Harrop, *writer*  
Lori Kirkpatrick, *designer*  
Keith Weller, *photographer*

For questions or comments, contact:  
jkovals1@jhmi.edu or 410-614-5044

© 2015 The Johns Hopkins University and  
The Johns Hopkins Health System Corporation.

For referrals or appointments to the  
Department of Surgery, call 443-997-1508

Non-Profit Org.  
U.S. Postage  
PAID  
Permit No. 5415  
Baltimore, MD

# JOHNS HOPKINS Surgery

SUMMER 2015



NEWS FROM THE JOHNS HOPKINS DEPARTMENT OF SURGERY

Inside



# 1

Proctectomy  
and  
Anastomosis  
for Lower  
Rectal Cancer



# 2

Expanding  
Options for  
Liver Transplant  
Patients



# 3

Two Aesthetic  
Approaches  
When Breast  
Cancer Tumors  
Are Small