

JOHNS HOPKINS ALL CHILDREN'S HOSPITAL

Evaluation of Sacral Dimples/Coccygeal Pits Clinical Pathway

Johns Hopkins All Children's Hospital

Evaluation of Sacral Dimples/Coccygeal Pits Clinical Pathway

Table of Contents

1. [Scope](#)
2. [Guideline Panel](#)
3. [Executive Summary](#)
4. [Published Data and Levels of Evidence](#)
5. [Clinical Practice Guideline](#)
6. [Summary](#)
7. [Glossary](#)
8. [References](#)
9. [Clinical Pathways Team Information](#)

Updated: 11/11/2021

Owners: Candice Guevara, DO

This pathway is intended as a guide for physicians, physician assistants, nurse practitioners and other healthcare providers. It should be adapted to the care of specific patient based on the patient's individualized circumstances and the practitioner's professional judgment.

Johns Hopkins All Children's Hospital

Evaluation of Sacral Dimples/Coccygeal Pits Clinical Pathway

SCOPE

This Clinical Practice Guideline (CPG) applies to:

All Children's Hospital, Inc., and

All Children's Health System, Inc.

o West Coast Neonatology, Inc.

Guideline Panel

Candice Guevara, DO, Neonatal Hospitalist

Nicole Nghiem, MD, Neonatal Hospitalist

Jamie Aron, DO, Neonatal Hospitalist

Andrea Komis, MD, Neonatal Hospitalist

Sandra Brooks, MD, Neonatologist

Jennifer Kucera, MD, Pediatric Radiology

Luis Rodriguez, MD, Pediatric Neurosurgery

Executive Summary

Coccygeal pits are the most common cutaneous anomaly detected on neonatal spinal exam. This is of importance, because in contrast to coccygeal pits, **sacral dimples** may be associated with underlying spinal dysraphism. Multiple studies have demonstrated that simple coccygeal pits are often benign variants and do not require any further evaluation with imaging. By establishing screening guidelines, health care expenditures can be reduced and parental anxiety relating to this issue can be prevented.

While multiple studies (described below) have shown that ultrasound can be useful when a sacral dimple is identified, these studies do *not* differentiate between a true, rare sacral dimple (located over the sacrum above the rectal crease) and a common coccygeal pit (located over the top of the coccyx within the rectal crease). The **coccygeal pit** is a normal physiologic variant without a connection to intraspinal components and does not require imaging whereas a true **sacral dimple** is concerning and requires imaging. The initial step is to truly differentiate a coccygeal pit from a sacral dimple.

Definitions

1. Coccygeal pit

- a. located BELOW the level of a symmetric intergluteal crease directly above the tip of the coccyx (pictures below).

2. Sacral dimple

- a. indentation overlying the sacrum located ABOVE a normal rectal crease (pictures below)

Published Data

1. Ultrasound to evaluate neonatal spinal dysraphism: A first-line alternative to CT and MRI (2019)

- A. Review of embryologic origins and imaging of spinal dysraphisms
- B. US is well-established to investigate the spinal canal in pregnancy and younger infants to recognize many abnormalities
- C. Proper evaluation of spinal malformations with spinal US is a safe and cost-effective alternative in patient management in appropriate cases and should be considered as a first-line imaging for neonates suspected of spinal anomalies
- D. A negative high-quality, comprehensive US study of the neonatal spine is helpful to rule out a wide variety of complex spinal cord anomalies
- E. Need for sedation, thermal instability of infants, and high cost make the use of spinal MRIs impracticable for screening purposes
- F. A normal US study of the spinal cord may limit/prevent unnecessary spinal MRI studies in the challenging neonatal time period

2. Ultrasonography and magnetic resonance imaging evaluation of pediatric spinal anomalies (2016)

- A. Observational study over the course of one year
- B. Analyzed 38 cases with spinal dysraphism
- C. 79% of cases (23 out of 29) showed agreement between ultrasound and MRI, 20% (6 out of 29) showed partial agreement between ultrasound and MRI
- D. Of the partial agreement cases, ultrasound missed tethered cord and syrinx in three cases, one case of split cord, one case of small lipomatous component and one case of intradural lipoma

3. Screening for spinal dysraphisms in newborns with sacral dimples (2016)

- A. Concerning findings warranting further work-up: dimples located superior to natal cleft or more than 2.5 cm from the anal verge, dimples larger than 5 mm in diameter, multiple dimples, or dimples associated with other cutaneous stigmata including hypertrichosis, hemangiomas, skin tags or duplicated gluteal clefts
- B. Simple solitary dimples located within the gluteal cleft without evidence of drainage do not require further evaluation

C. Retrospective study at University of North Carolina Children's Hospital from Aug 30, 2008 to Dec 31, 2014; N=151 infants with screening spinal ultrasounds

- 32% infants with simple sacral dimple
- 34% with isolated deep sacral dimple
- 12% with multiple sacral dimples
- 13% simple sacral dimple plus another cutaneous finding
- 2% large sacral dimple >5 mm
- 5% duplicated gluteal cleft

Results: Majority (80%) of infants had normal spinal US

-Of the 20% of infants with abnormal spinal US that underwent spinal MRI only 5% had an abnormal spinal MRI

-Neurosurgical consultation was documented for 13 infants with either abnormal US or MRI, of which only 2 required neurosurgical management for a tethered cord

D. Infants with additional congenital anomalies are at higher risk of spinal dysraphism compared with otherwise healthy infants with sacral dimples

-Retrospective study by Chern et al. N=1116 infants; significantly higher positive predictive value for detecting OSD among infants imaged due to the presence of congenital anomalies compared with those imaged for suspicious cutaneous findings alone (28% vs 5.9%)

-Positive predictive value for infants with congenital anomalies vs cutaneous stigmata going on to require neurosurgical intervention was higher for those with congenital anomalies (6.7% vs 0.85%)

-Infants with congenital anomalies are at high risk for spinal dysraphism and may require separate screening guidelines

4. The simple sacral dimple: Diagnostic yield of ultrasound in neonates (2015)

A. Multi-institutional cohort study of patients referred to both Nationwide Children's Hospital and Cincinnati Children's Hospital for a screening lumbar spine US for a simple sacral dimple to determine frequency of a tethered cord

B. Out of 3,884 healthy children screened, 96.6% had normal sonograms and (133) 3.4% had abnormal sonograms

C. Only 5 out of the 3,884 (0.13%) infants underwent surgical intervention and 4 of 5 were found to have a tethered cord

D. Risk of significant spinal malformations in asymptomatic, healthy infants with an isolated simple sacral dimple is exceedingly low

5. The accuracy of abnormal lumbar puncture sonography findings in detecting occult spinal dysraphism: A comparison with magnetic resonance imaging (2012)

A. Retrospective study of 1,273 infants who underwent lumbar ultrasound at Children's Hospital in Birmingham, Alabama

B. Infants suspected of having a spinal dysraphism on exam or with multiple congenital anomalies underwent a lumbar ultrasound

C. 103 patients with abnormal ultrasound underwent subsequent MRI

D. Lumbar ultrasound had poor sensitivity at detecting thickened or fatty filum as well as abnormal conus level

E. Abnormal lumbar ultrasound findings have poor sensitivity and good specificity at detecting anatomical findings consistent with occult spinal dysraphism. Findings must be confirmed with MRI

6. Sacral Dimples (2011)

A. 2-4% of all children have a dimple identified in the sacrococcygeal region

B. A simple sacral dimple has no clinical significance and should be considered anatomic variations of normal

C. Dimples that require further evaluation: multiple dimples, dimple diameter >5 mm, location greater than 2.5 cm above the anal verge and association of dimple with other cutaneous markers

D. A deviated or duplicated gluteal cleft should raise concern for OSD, whether or not a dimple is present

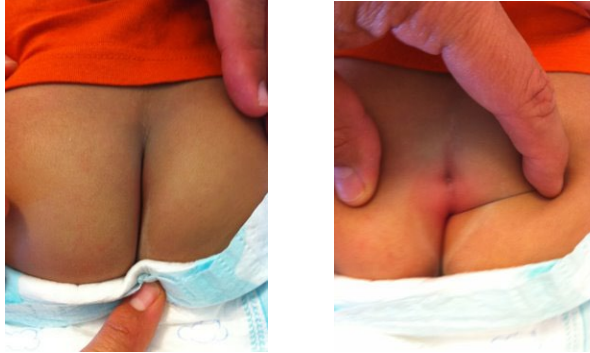- E. Infants with a simple sacral dimple, with evidence of abnormal neurologic or orthopedic exam findings should be further evaluated
- F. Decision to use ultrasound vs MRI as first-line imaging is somewhat institution dependent
- G. If ultrasound findings are abnormal, MRI is more reliable and exact in diagnosing OSD
- H. Any sacral dimple associated with other cutaneous findings (ex: hypertrichosis, hemangioma, etc) require immediate MRI and neurosurgical referral

7. Coccygeal Pits (2000)

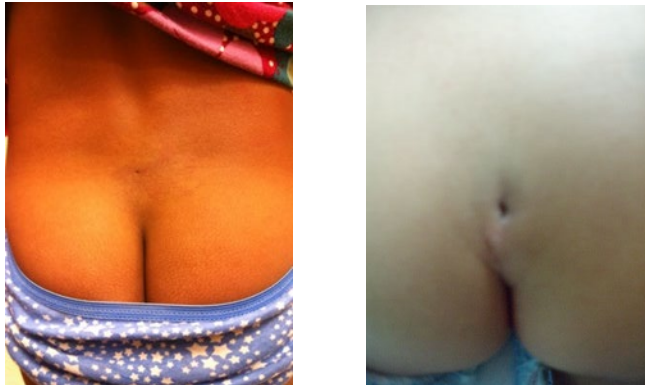
- A. Intergluteal dorsal dermal sinuses are relatively common lesions that do not seem to be associated with significant risk of spinal cord and intraspinal anomalies
- B. Simple intergluteal dorsal dermal sinuses without other cutaneous findings do not require radiographic or surgical evaluation and treatment
- C. Literature search of patients with presumed association between coccygeal pit and neuro infection/intradural pathology between July 1978-1998: N = 1000 pt's with simple coccygeal pits identified. Only 7 cases associated with abnormalities, 5 of which had coccygeal pits that were not in isolation
- D. Herman et al performed spinal US on 53 infants with coccygeal pits: no intraspinal anomalies identified
- E. Gibson et al prospectively examined 95 neonates, 75 had isolated coccygeal pits; no abnormality of spinal axis found in those with coccygeal pits
- E. On operative correlation, ultrasound findings were confirmatory in 91% of cases and MRI was confirmatory in 100% of cases
- F. MRI is better modality for showing concurrent abnormalities and provide additional anatomical details for surgical planning

Clinical Practice Guideline

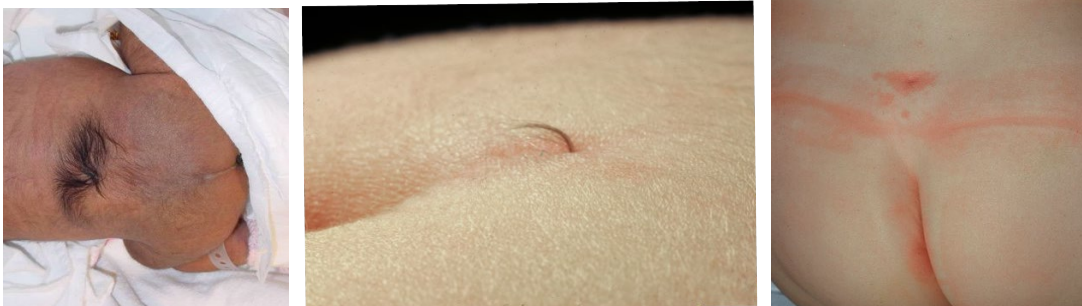1. Differentiate between a coccygeal pit and a sacral dimple.
2. **Coccygeal pit:**
 - a. Located **BELOW** the level of a symmetric intergluteal crease directly above the tip of the coccyx



3. **Sacral dimple:**
 - a. Indentation overlying the sacrum located **ABOVE** a normal rectal crease OR with an abnormal rectal crease



4. Any **sacral dimple**, regardless of whether or not you can visualize the base, requires immediate neurosurgical referral for MRI imaging
5. A **coccygeal pit** does not require any further imaging or evaluation
6. Any abnormal cutaneous findings in the coccygeal/sacral region, such as hypertrichosis or a skin tag, or an abnormal neuro exam, require immediate neurosurgical referral for MRI imaging



Summary

1. A coccygeal pit does not require any further imaging or evaluation
2. A sacral dimple requires immediate neurosurgery referral and MRI imaging

Glossary

Occult Spinal Dysraphism (OSD)

Ultrasound (US)

Magnetic Resonance Imaging (MRI)

References

1. Orman, G. et al. (2019). Ultrasound to Evaluate Neonatal Spinal Dysraphism: A First-Line Alternative to CT and MRI. *Journal of Neuroimaging*, 5, 553-564.
2. Dhingani, D. et al. (2016). Ultrasonography and magnetic resonance imaging evaluation of pediatric spinal anomalies. *Journal of Pediatric Neuroscience*, 11 (3), 206-212.
3. Wilson, P. et al. (2016). Screening for Spinal Dysraphisms in Newborns With Sacral Dimples. *Clinical Pediatrics*, 55 (11), 1064-1070.
4. Kucera, J. et al. (2015). The Simple Sacral Dimple: Diagnostic Yield of Ultrasound in Neonates. *Pediatric Radiology*, 45, 211-216.
5. Chern, J.J. et al. (2012). The accuracy of abnormal lumbar puncture sonography findings in detecting occult spinal dysraphism: A comparison with magnetic resonance imaging. *Journal of Neurosurgery*, 2, 150-153.
6. Zywicke, H.A. et al. (2011). Sacral Dimples. *Pediatrics in Review*, 32 (3), 109-114.
7. Weprein, B. et al. (2000). Coccygeal Pits. *Pediatrics* 2000; 105; e69.

Clinical Pathway Team

Evaluation of Sacral Dimples/Coccygeal Pits

Clinical Pathway

Johns Hopkins All Children's Hospital

Owner(s): Candice Guevara, DO

Also Reviewed by:

Infectious Diseases:
Hospitalists:
Intensive Care:
Emergency Center:
Resident Physicians:
Nursing:
Pharmacists:
Johns Hopkins Children's Center Team:
Others:

Clinical Pathway Management Team: Joseph Perno, MD; Courtney Titus, PA-C

Date Approved by JHACH Clinical Practice Council:

Date Available on Webpage: 2/24/2022

Last Revised: 11/11/21

Last Formatted: 11/11/21

Disclaimer

Clinical Pathways are intended to assist physicians, physician assistants, nurse practitioners and other health care providers in clinical decision-making by describing a range of generally acceptable approaches for the diagnosis, management, or prevention of specific diseases or conditions. The ultimate judgment regarding care of a particular patient must be made by the physician in light of the individual circumstances presented by the patient.

The information and guidelines are provided "AS IS" without warranty, express or implied, and Johns Hopkins All Children's Hospital, Inc. hereby excludes all implied warranties of merchantability and fitness for a particular use or purpose with respect to the information. Johns Hopkins All Children's Hospital, Inc. shall not be liable for direct, indirect, special, incidental or consequential damages related to the user's decision to use the information contained herein.