

AN OPERATION FOR THE CURE OF INCONTINENCE ASSOCIATED WITH EPISPADIAS

HUGH H. YOUNG

James Buchanan Brady Urological Institute, Baltimore, Maryland

In a previous article (16) the author published a new technique for the radical cure of epispadias. This operation was not intended for cases associated with incontinence. Since then three patients with epispadias associated with complete incontinence have appeared at this clinic and the author, having devised a method for the radical cure of the incontinence, begs leave herewith to report two of these in full.

The question is interesting because we have been unable to find in the literature any similar operation, or in fact, any operation in which a restoration of the vesical neck, the internal or external sphincters to cure incontinence was attempted. I have also been unable to find any male case in which by any procedure the incontinence of urine was radically cured. It has been acknowledged for many years that the external procedures directed to repair the defect of epispadias in the male are powerless to cure incontinence. We have not the space to discuss the developmental anomaly responsible for the various degrees of epispadias, but we may quote from a monograph by Dr. Berry Hart (1).

The cloacal membrane, as was first pointed out by Kölliker, and afterwards confirmed by others, has at one time no mesoblast, and is thus a part structurally weak. The upper boundary of this membrane is the navel, and its lower the junction of end-gut and entodermal cloaca. In the adult this lower point is on the perineal body in front of the anus, as in the rare malformation, viz., persistent end-gut in a female child; I found this part of the gut attached to skin in front of the anus. In the adult, therefore, the cloacal membrane is represented by the mesial region from navel back to perineal body—the anterior boundary of bladder, pubes, urethra and vestibule.

The best explanation of extroversion is afforded by the facts now known as to bladder development and the cloacal membrane. The bladder in the human female, is not developed from allantois except at its apex, but is derived along with the urinogenital sinus from the anterior division of the entodermal cloaca. This cloaca has the cloacal membrane as its anterior boundary and as this boundary has no mesoderm at one period, it may yield or cleave. This yielding, if complete, necessarily exposes all that is derived from the anterior gut division, viz., bladder, urinogenital sinus, lower third of vagina as in Champney's case. Less degrees of fissure in linear extent or depth give the other lesions. These are therefore explained, as Keibel has so well shown, by the actual development of the parts plus some bursting or dilating cause which, if it does occur (and of that we have as yet no proof) must do so at an early period of embryonic life.

The most important article on epispadias with incontinence by Stiles (8) concerns only the female, but as many of the problems are similar I shall quote from this paper at length:

It is unnecessary to give a detailed description of all these lesions. Suffice it to say that they consist in order of severity of: partial epispadias, where the deeper part of the dorsal wall of the urethra is developed; complete epispadias, where the dorsal wall is entirely absent; and subsymphyseal extroversion, where the sphincter at the neck of the bladder is deficient and there is more or less protrusion below the symphysis of the mucous membrane of the posterior wall of the bladder. It is often impossible to say whether one is dealing with a complete epispadias or a slight degree of subsymphyseal extroversion. From the practical point of view the two conditions may be classed together, as they both give rise to incontinence and call for the same treatment.

The indications for treatment are obviously twofold, namely, to rid the patient of the incontinence, and to repair the cleft condition. It is the incontinence and not the deformity which causes the patient to seek advice, and it is this condition which has so severely taxed the ingenuity of the surgeon. Time will not permit to describe in detail the various operative procedures which have previously been adopted. Moreover, the results of these procedures have proved so disappointing that I shall content myself with referring the reader to the admirable papers of Dr. J. W. Ballantyne (1895) (2) and Nové-Josserand and

Cotte (1907) (3). The former author, after describing a typical case in an unmarried woman aged twenty, who sought advice at his clinic at the Edinburgh Western Dispensary, gives a historical and chronological résumé of all the literature on the subject. He found records of thirty-three cases, and appends a full bibliography. Nové-Josserand and Cotte, after describing a case in a girl of five and one-half years of age, cover much the same ground as Dr. Ballantyne. They found records of thirty cases, and they give an admirable epitome of the operative technique of the eighteen cases which were subjected to surgical treatment. In none of these eighteen cases were the ureters transplanted. In all except one (in which Mr. Makins (4) closed the abnormal urethra and substituted for it a suprapubic fistula, with the object of making it easier for the patient to wear an artificial receptacle for the urine), a plastic operation was carried out on the vulva and urethra with the double object of repairing the cleft and at the same time dealing with the urethra in such a way as to endeavor to overcome the incontinence. The former object is not difficult to attain, but as might be anticipated the procedures directed towards curing the incontinence almost invariably failed. The various methods employed have consisted either simply in narrowing with lengthening. The narrowing was effected either by simple cauterization, by suturing the raw edges obtained by lateral incisions, by urethral colporrhaphy, or by a plastic operation combined with torsion. A combination of lengthening and narrowing of the urethra was attained in one of three ways: (1) by dissecting down a triangular flap from the mucocutaneous trough above the abnormal meatus so as to restore the superior wall of the urethra; (2) by the formation of two lateral flaps combined with supraurethral colporrhaphy; (3) by combining lengthening with torsion of the urethra. As might be anticipated, most of the operators found no difficulty in attaining a satisfactory cosmetic result by restoring the anterior commissure and uniting the two halves of the clitoris above the urethral orifice. In all but three cases, however, the incontinence persisted, and in those in which continence was said to have been obtained, it is difficult to gather how far the cure was complete and permanent. As Nové-Josserand remarks: "By lengthening the urethra, and restoring the meatus to its normal position, a certain amount of curving of the canal is probably produced, and this change of direction of the urethra, which has been both lengthened and narrowed, may be sufficient to bring about a temporary mechanical closure of the bladder. In all the cases reported, it is evident that the continence of the urine is obtained by

the purely mechanical means of damming back the urine, and that the sphincter is not in any way responsible for it. When the vesical pressure attains a certain degree, the obstacle which has been created to close the urinary reservoir is forced and the urine escapes." Quite recently, Goebell of Kiel (5) has introduced a new principle of treating epispadias in the female, namely, that of utilizing the pyramidal muscles to form a vesical sphincter. By dissecting upwards a flap by means of a transversely curved suprapubic incision, these muscles are freed laterally and at their apices. After separating the recti and freeing the neck of the bladder from the vagina, the pyramidales are turned downwards and stitched together in the space between the neck of the bladder and the anterior wall of the vagina. The muscles are also united above the neck of the bladder, and if they are sufficiently well developed they are made to cross one another before they surround the neck of the bladder. By this procedure, Goebell maintains that he converts the pyramidal muscles into a voluntary sphincter. The nerve supply, which is derived from the termination of the last intercostal nerve, enters the muscle laterally at its base and is not therefore interfered with. As the result of this operation the child's condition was so far improved that she occasionally slept the whole night through without wetting the bed, but she was unable to keep herself dry when playing or walking about. Still another method is that of Hackenbruch (6), who, after exposing and freeing the anterior surface of the bladder by a suprapubic incision, lengthens its neck by the application of several transverse reefing sutures. Goebell, however, claims his method is superior, from the fact that he provides the neck of the bladder with a sphincteric apparatus made up of a voluntary muscle.

Stiles further states:

Before operating on my own cases, I felt that if the incontinence were to be really cured there was no alternative but to transplant the ureters into the intestine, and this in spite of the fact that experiments on animals, as well as the reported cases in which this procedure had been carried out on the human subject, had given very unsatisfactory results, and had been attended with a high mortality. The fatal results following transplantation of the ureters into the intestine are due either to immediate or remote complications. Chief amongst the former is peritonitis, due either to peritoneal contamination at the time of operation or to subsequent leakage of urine or feces, to undue traction of the urethra, or to local sloughing. Of the remote complications the

most important is that which results from an ascending infection of the kidney (either apart from or associated with hydro- or pyonephrosis), the result of cicatrization and stricture at the seat of implantation. It is to be noted, however, in epispadias without extroversion of the bladder, that in order to transplant the ureters along with their orifices, the first step in the operation would entail gaining access to them either by opening the bladder suprapubically or by an extensive perineal dissection, either of which procedures would greatly complicate the operation as well as render it a formidable one. It seems to me therefore that the best course to adopt in epispadias without extroversion of the bladder is to expose and divide the ureters as close to the bladder as possible by the intraperitoneal route, and then to transplant them separately into the lower part of the pelvic colon. This brings us back to the vexed question as to how this can best be done so as to guard as far as possible against an ascending kidney infection. In 1892, Maydl, following Tuffier's suggestion, introduced a new principle into the operation; this consisted in transplanting, not the divided ureters, but an elliptical portion of the trigone of the bladder containing the ureteric orifices into the pelvic colon, the object being to retain the natural sphincteric fibers surrounding their orifices and so to prevent regurgitation of the intestinal contents and consequent infection of the kidneys. This method has the further advantage of preventing stricture and hydronephrosis. According to Zesas, 71 of the 97 cases operated on by Maydl's method recovered. Of the 26 fatal cases, 2 died of shock, 13 of pyelonephritis, 5 of peritonitis, 3 of infiltration of urine, 2 of kinking of the ureters. Ascending infection of the kidneys might be the cause of death up to two years after operation. The sphincteric control over the urine seemed to be satisfactory in most cases. Berg's method of forming a bladder out of an isolated portion of small intestine, Gersuny's plan of transplanting the ureters along with the trigone into the isolated rectum and then pulling the lower end of the pelvic colon through the pouch of Douglas and bringing it out at the perineum within the sphincter ani; and, lastly, Subbotin's method of making a communication between the ectopic bladder and the rectum and forming a reservoir for the urine out of the mucous membrane of the rectal canal, although ingenious and theoretically attractive, are too complicated as well as too formidable to be selected in preference to the more simple procedure. Steinke sums up the results obtained as follows: 'Of the 35 cases recorded above, 2 have no statement as to whether or not the patient lived after the operation. However, 15 are reported as

recovering, and 18 resulted fatally, making a general mortality of about 54.5 per cent. Two cases died of tuberculosis of other organs, thus making the mortality from the operation and its effects 55 per cent. Of the 15 cases reported as living, two are unilateral implantations, and unilateral cases are really no test, as there still remains one good kidney to carry on the function. This leaves 15 of the 27 bilateral cases recorded as living after four weeks or more, making a mortality of 55.5 per cent. These results show that under certain conditions the ureters may be transplanted successfully. The ultimate results are, however, uncertain, and fatality is apt to occur under the best circumstances."

An extensive article by Steiner (9) in 1873 gives in great detail the literature and a résumé of all the cases which had been reported up to that time. A careful review of this work shows no case in which the surgeon attempted to do more than perform a plastic operation upon the epispadias to close the defect. No attempt to restore the neck of the bladder or the sphincters, either external or internal, was carried out. In a few cases, the operator reported a slight improvement in the incontinence as a result of these partial procedures. Several patients were able to retain urine while in bed and two for an hour or two during the day, but no case in which restoration to normal urination followed the operation is recorded.

Page (10) reported a case of epispadias with partial incontinence operated on by Cantwell's method, in which complete control of urine resulted. The patient is reported to have been able to retain urine for 7 hours during the day and all night. This case, as noted, was not one of complete incontinence and is therefore, unlike those we have recorded.

Stettiner (11) discusses the cure of incontinence of urine associated with epispadias in females and refers again to a method of constructing the vesical orifice by means of three stitches placed in the wall of the urethra and then drawn together, narrowing the tube, but without excision. No excision and no attempt to restore the vesical neck was made. He also describes the use of the pyramidalis muscles according to the method of Goebell, above referred to. The results obtained, however, were said to be unsatisfactory.

Stoeckel (12) in 1920 reviews the procedures previously described and also comments on the use of a plastic through the vagina, in which an attempt was made to tighten the vesical neck by means of vaginal plastic, but again without satisfactory results.

Barney (13) states that he relies upon training the sphincters to combat the incontinence in these cases, after having closed the epispadiac defect by means of a plastic, in which the prepuce is used. No details of the results obtained in incontinence are given.

The author has been interested in the treatment of incontinence since his publication in 1908 (14) of a new procedure for the cure of incontinence of urine by suture of the urethra and vesical sphincters in a case of incontinence following median perineal urethrotomy, in which both the external and internal sphincters had been injured. In this case the incontinence was complete and cystoscopy showed that both internal and external sphincters were widely dilated as the result of an incision made along the floor of the urethra into the bladder. The operation consisted of: first, suprapubic cystostomy; excision of mucous membrane along the posterior portion of the vesical orifice uncovering the muscle; closure or narrowing of the prostatic orifice by transverse sutures of catgut. Second, exposure of membranous urethra through perineum; excision of mucous membrane of the floor on each side; exposure of sphincter muscles; closure with several layers of catgut sutures. Third, suprapubic drainage. The result obtained in this case was perfect. The patient was restored to entirely normal urination, able to retain urine all night and several hours during the day.

Since then, several cases of incontinence of urine, mostly post-operative, either from perineal lithotomy, urethrotomy, or prostatectomy perineal or suprapubic, have been operated upon by this procedure with satisfactory results. The subject has been discussed at length by the author in a recent article (15). In this paper, a particularly difficult case of incontinence associated with rectourethral fistula, in which a complete cure was obtained, is recorded (see figs. 1 to 4). In these cases of

operative incontinence, however, the problem was to restore sphincteric control, generally both external and internal, by repairing the injury along the floor of the urethra, thus differing

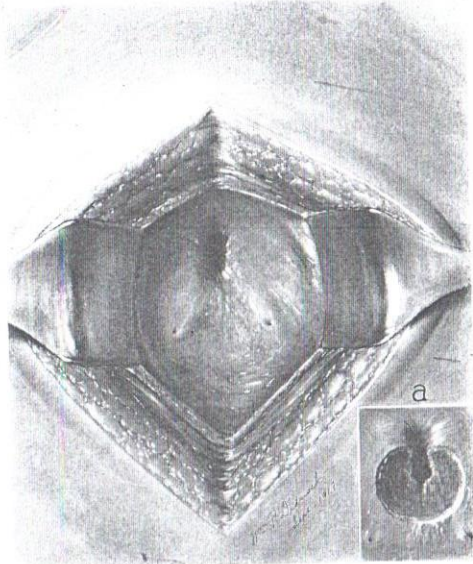


FIG. 1. VIEW OF BASE OF BLADDER SHOWING DILATED INTERNAL VESICAL SPHINCTER

Insert (a) shows area denuded of mucous membrane, preparatory to suturing

radically from the problem presented in cases of epispadias with incontinence which are due to failure of coaptation or muscular development along the roof of the urethra, both at the vesical neck and in the region of the triangular ligament and external

sphincter. The condition present in these cases is shown in figures 8 and 9, and careful examination convinced the author that, in order to restore the vesical neck and obtain a radical cure of the incontinence with complete restoration to normal

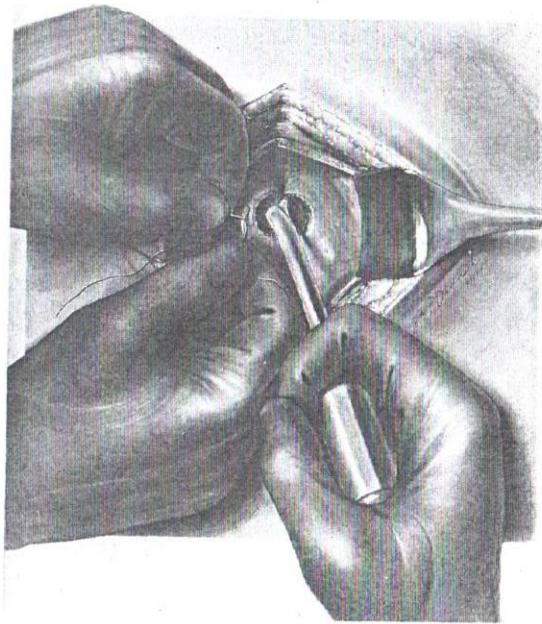


FIG. 2. THE NEEDLE HAS ENTERED THE TISSUE AND RETURNED, POINTING TOWARD THE OPERATOR

Assistant hooks suture in eye of needle. (In deep wounds it is necessary to carry the suture down to the needle with a special forceps.)



FIG. 3. "BOOMERANG NEEDLE HOLDER"

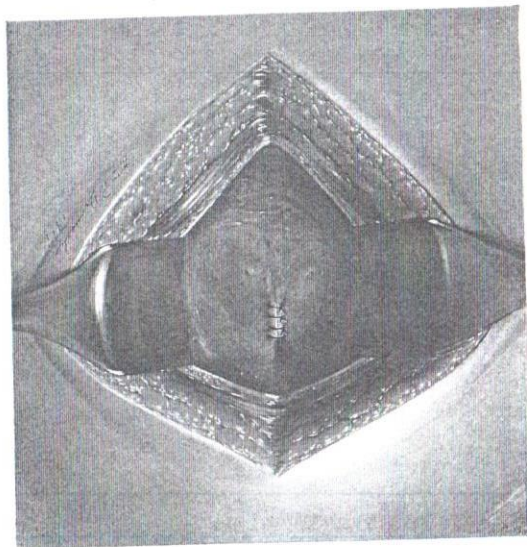


FIG. 4. SUTURE-LINE AFTER COMPLETION OF PLASTIC OPERATION UPON INTERNAL SPHINCTER

urination, it was necessary to attack the roof of the urethra and carry out a plastic to repair completely the internal and external sphincters. This has been satisfactorily accomplished, as will be shown in the two cases which follow. In both of these cases the primary operation was suprapubic and intraurethral to cure the incontinence and later the plastic operation upon the epispiadis by the technique described by the author (16).

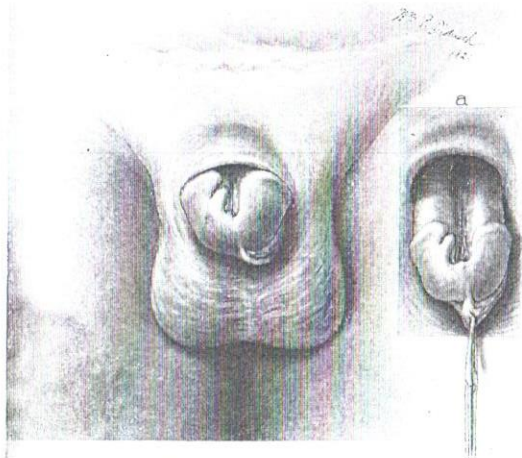


FIG. 5. SHOWING THE EPISPIADIAS IN CASE I

Glans and shaft pulled down to show the great depth of the defect. Glans is only partially cleft.

Case I. No. 8583 BUI, V. W. C., eighteen years old, single. Admitted March 3, 1920.

Complaint: Deformity of penis and incontinence of urine.

Family history: Negative.

Patient was born with deformity of penis and incontinence of urine. At the age of fourteen he underwent an operation for epispiadis which

was entirely unsuccessful. Patient has never attempted sexual intercourse although he has erections. No history of venereal disease. In recent years owing to a constant leakage of urine and the resultant odor the patient has had to quit school.

Examination: Patient is a strong, well-developed, healthy looking young man. Heart, lungs and abdomen negative. Suprapubic regions negative.

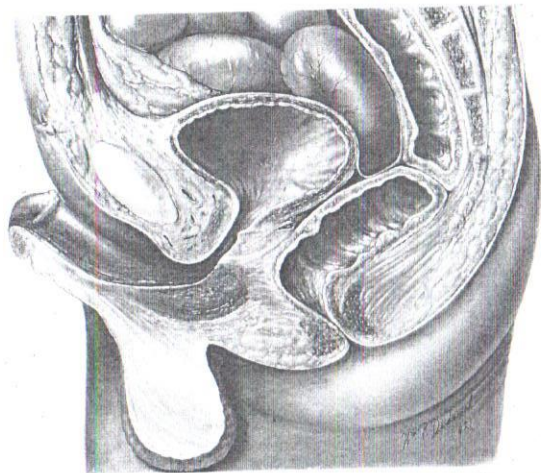


FIG. 6. SECTIONAL VIEW TO SHOW THE DILATED PROSTATIC ORIFICE (INTERNAL SPHINCTER) AND MEMBRANOUS URETHRA (EXTERNAL SPHINCTER)

Genitalia: Complete epispadias is present, penis being directed upward and lying against the pubis. Scrotum is normal in size and testes, epididymes and cords are normal. Penis is broad and along the dorsum there extends a fairly deep groove which represents the urethra. The roof of the urethra is absent for a distance of about 2 inches and beyond that is in the form of a deep funnel which extends down into the bulbous urethra; the corpora cavernosa are partially separated by the troughlike

urethra. The urethral groove extends down through and almost completely divides the glans into two halves. The penis is short, broad and curved upward on the pubis. The prepuce is divided and is redundant upon the under surface of the glans on each side. The condition present is shown in the drawing (figs. 5 and 6). By drawing the penis out by the scrotal hood a deep funnel-like urethra is seen in front of the symphysis pubis and into this the finger can be inserted, showing a distinctly dilated external sphincter. Rectal: Anal sphincter is normal, prostate is smaller than normal, median furrow and notch wide and shallow. Each lateral lobe is approximately the size of the distal phalanx of the index finger. The seminal vesicles are apparently normal and somewhat distended.

Cystoscopy: Cystoscope enters easily, no stricture, no residual urine, bladder capacity 175 cc. Tonicity good. When more than 175 cc. of fluid entered the bladder the fluid escaped around the shaft of the instrument, showing definitely dilated sphincter. The ligamentum inter-uretericum is concave and less developed than usual. The ureteral ridges are thin but fairly prominent, orifices apparently normal. The trigone is apparently less muscular than usual. The uvula vesicae is distinctly less prominent than normal. Cystoscope can be drawn out into the posterior urethra and shows a dilated internal orifice; verumontanum is apparently larger than normal and on the left there is a fairly deep depression in front of the median portion of the prostate. Study of the prostatic orifice shows a dilated orifice and an absence of the usual sharply defined margin. The bladder mucosa is apparently normal. No cellulose or diverticula. Study of the region of the external sphincter not very satisfactory, apparently somewhat dilated. Urethroscopy shows a definite dilatation of the internal sphincter and imperfect closure of the external sphincter. X-rays show a separation of more than 1 cm. of the symphysis pubis (fig. 7). Preliminary study: Patient complained principally of incontinence which was present almost always night and day. An attempt was made to dilate the bladder and to try to teach the patient to control his urine by exercises; under this treatment the bladder was dilated from 175 to 230 cc. and the patient seemed to gain some control but it was, at best, imperfect and he frequently wet the bed at night and his clothes during the day time. Accordingly it was decided to carry out an operation to relieve the condition.

October 8, 1920: Operation, Young Nitrous-oxide, oxygen, ether. Suprapubic cystostomy and discovery of dilated internal sphincter. Excision of roof of urethra in prostatic and membranous portions. Plas-

tic operation to restore a normal internal prostatic orifice, internal sphincter and external sphincter. An incision was made in the median line about 5 inches long and the bladder widely opened and an excellent view obtained. The prostatic orifice was widely opened as

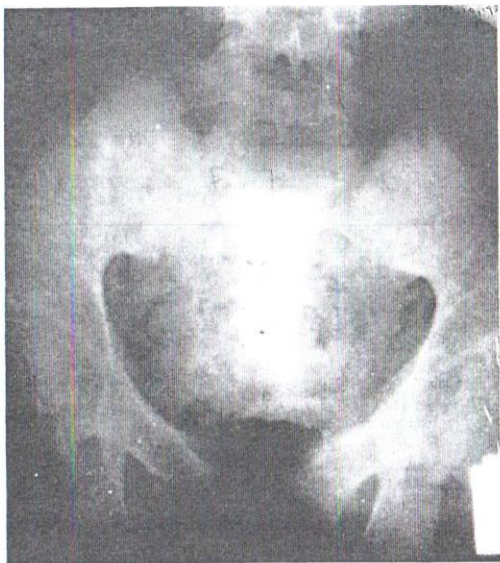


FIG. 7. X-RAY SHOWING MARKED SEPARATION OF THE SYMPHYSIS PUBIS (1.5 CM.)

A little thorium remains in the bladder after previous examination

shown in figure 8a. The entire prostatic urethra was apparently markedly dilated and there was no evidence of sphincteric action present, the tissues in front of urethra were thin and fibrous. On each side and posteriorly apparently there was muscle present. A finger in-

serted into the posterior urethra passed without difficulty out through the external sphincter and another finger inserted through the epis-padias into the bulbous urethra easily met the finger which had been

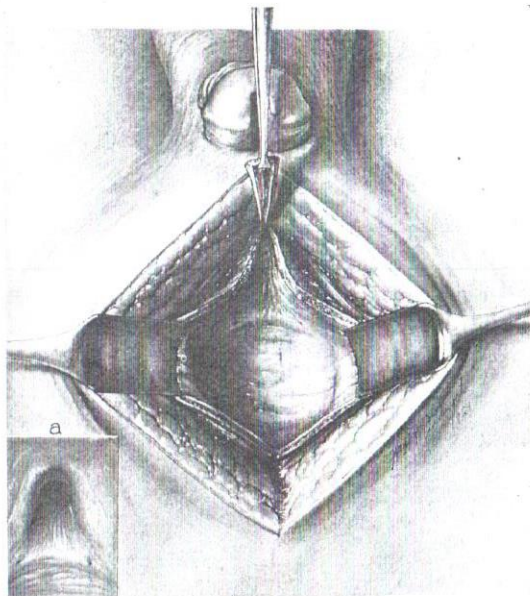


FIG. 8. (a) DILATED CONDITION OF PROSTATIC ORIFICE AND ATROPHY OF THE TRIGONE

Excision of anterior wall of dilated prostatic urethra also shown

passed from the bladder outward, thus showing marked dilatation, not only of the prostatic urethra but of the membranous urethra and external sphincter. Investigation showed little or no "triangular ligament" and the absence of musculature in front of the urethra in the bulbo-

membranous region. The trigone was distinctly atrophic in appearance but the ureteral orifices looked normal. The operator decided to confine his attention to curing the incontinence and thought it necessary to attack not only the internal sphincter and vesical orifice but the external sphincter as well. Accordingly the anterior wall of the prostatic urethra

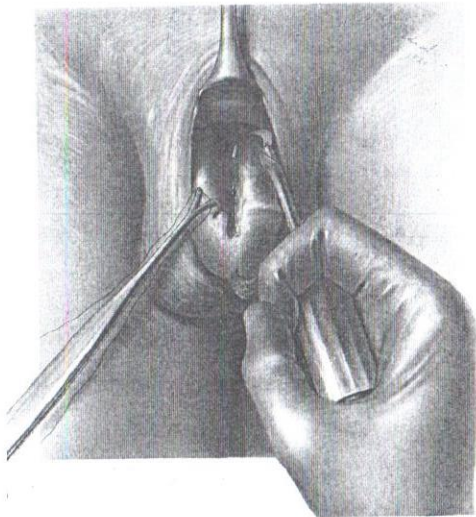


FIG. 9. THE ROOF OF MEMBRANOUS URETHRA EXCISED THROUGH EPISPADIC CAVITY

was excised as shown in figure 8. The adjacent portion of the anterior wall of the bladder was also excised so as to leave sufficient tissue which when closed would form a fairly normal prostatic urethra. Examination showed that there was muscle on each side which could be drawn together. There still remained the dilated external sphincter and it was found possible by inserting a narrow retractor to obtain a good view of

the roof of the membranous urethra through the epispadia and dilated bulbous urethra. A clamp was then inserted, grasping the roof of the urethra, and with a delicate knife the mucous membrane and adjacent tissues were excised along the roof of the membranous urethra until the

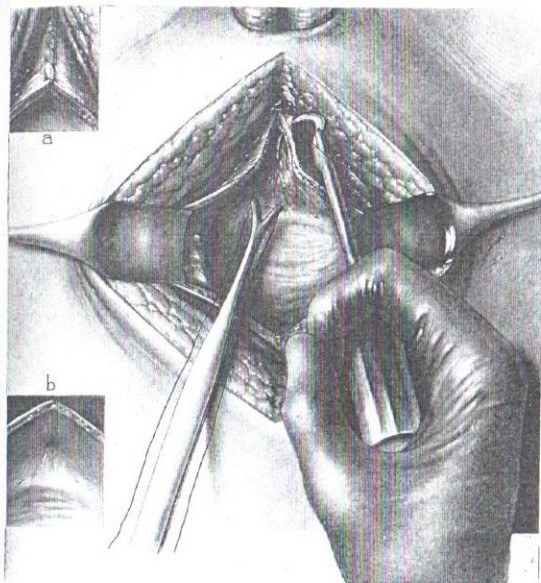


FIG. 10. SHOWING THE APPROXIMATION OF CUT EDGES OF PROSTATE WITH "BOOMERANG NEEDLE HOLDER" AND RESULTANT CLOSURE OF PROSTATIC ORIFICE

region of excision which had been carried out suprapubically was reached; in this way the entire roof of the prostatic and membranous urethra had been excised (figure 9). Through the suprapubic wound by means of a continuous chromicized catgut suture, which did not pene-

trate the mucous membrane, the prostatic urethra was closed, the muscle approximated at the vesical orifice and a tight internal sphincter produced. By a continuation of the same suture the adjacent anterior

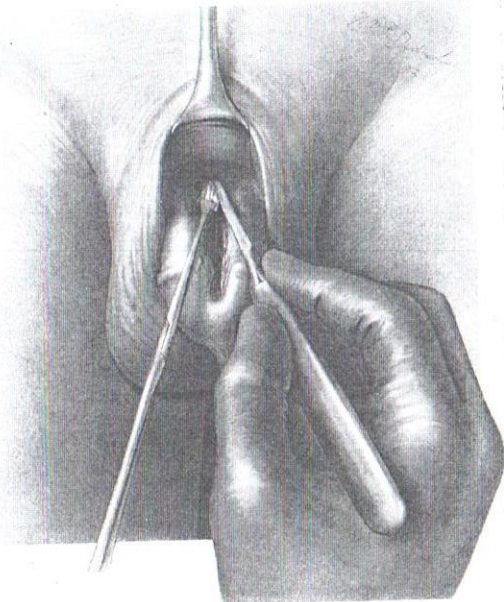


FIG. 11. APPROXIMATION OF ROOF OF MEMBRANOUS URETHRA WITH CONSEQUENT CLOSURE OF THE EXTERNAL SPHINCTER

wall of the bladder was approximated (fig. 10). The view obtained then in the bladder was that of a normally closed prostatic urethra whereas previously there was a funnel-like neck which extended into the urethra. By means of the "boomerang needle holder" a suture of chromicized catgut was placed in the roof of the membranous urethra through the

epispatias and dilated posterior urethra, as shown in figure 11. Investigation showed that the membranous urethra was tightly approximated. The bladder was closed with the continuous chromicized catgut suture, leaving an opening at the upper angle for catheter drainage. The recti muscles and skin were drawn together with interrupted silver wire sutures with prevesical drain at the lower angle, catheter drainage for the bladder. No operation to close the epispatias was done at this time.

Comment: The plastic operation to secure approximation similar to normal closure of the prostatic and membranous sphincters was apparently entirely satisfactory.

Convalescence, October 12: Patient has done well, suprapubic drainage satisfactory. One per cent mercurochrome injected in small amounts into the bladder and bulbous urethra. No evidence of infection. October 19: Patient has done well, drains freely through suprapubic tube. Mercurochrome instillation daily. October 23: Suprapubic tube has been removed but the patient voids through the penis and has partial control. October 30. Catheter replaced in suprapubic sinus and attached to Davis vacuum bottle. December 7: Patient has had an excellent convalescence, suprapubic drainage has been maintained in view of second operation. At times the patient has voided urine in fair amount through the urethra and has apparently complete control.

December 8, 1920: Operation, Young. Nitrous-oxide, oxygen, ether.

Plastic operation to repair and cure epispatias. The technique followed was similar to that previously described by author (16). Incisions were made on each side so as to give abundant tissue for a large urethra (figure 12). At the posterior angle the incision went down into the depths of the cavity towards the bulbous urethra and the skin on each side was elevated freely. At the glans penis the incision on the left extended only a short distance on the anterior surface of the glans, the new urethra being left continuous with the skin of the glans. On the right side the incision was carried deeply through the substance of the glans to the inferior surface so as to bisect the glans and displace the urethra to its normal position. The corpora cavernosa were widely separated by an incision to the right of the new urethra and after this had been approximated by continuous chromicized catgut suture and reinforced by a second line of continuous sutures, the urethra was depressed between the corpora cavernosa (fig. 13), the left corpus being rotated with it and two corpora then held in place above the new

urethra by a continuous line of chromicized catgut sutures. Another line of continuous sutures was placed to draw together the skin along the dorsum and the foreskin was drawn together with an additional con-

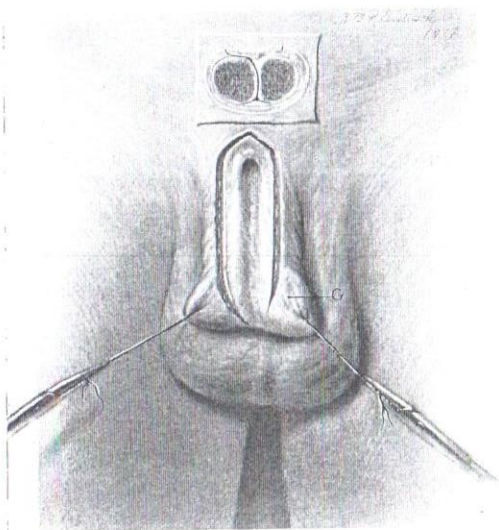


FIG. 12. SKIN INCISION

The penis is held in position by two traction sutures placed in glans (*G*). As indicated by the dark black line in the diagrammatic cross section, the incision on the left side goes only through the skin and down to the corpus, while, on the right, the dissection is carried down between the corpora until the skin of the under surface of the penis is reached.

tinuous chromicized catgut stitch. The glans penis was approximated above the new meatus with interrupted stitches of chromicized catgut (fig. 14). At the upper angle of the wound the tissues were not entirely approximated, a space being left for escape of serum.

Remark: At the end of the operation the penis looked quite normal, the glans was well formed and the tissues were well approximated. The suprapubic drainage was continued.

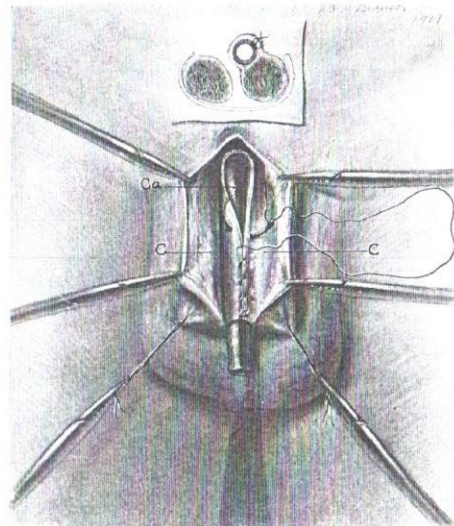


FIG. 13. THE NEW URETHRA IS BEING FORMED BY A CONTINUOUS SUTURE, BRINGING TOGETHER, OVER A CATHETER (*Ca*), THE EDGES PRODUCED BY THE ORIGINAL INCISION, AND CONVERTING THE ORIGINAL GROOVE INTO A TUBE

The attachment of the urethral tube to the left corpus may be distinctly seen both in surface view and cross section.

Convalescence, December 11: Patient had a chill followed by a rise of temperature to 105°. Examination showed slight edema of penis but no definite infection was made out. December 13: Patient has continued to have slight fever and pus can be expressed from the new

formed meatus. Injections of a small amount of 1 per cent mercurochrome have been carried out several times daily. December 18: Temperature has become normal and suppuration has ceased. Wound has not broken down and condition is excellent. December 28:

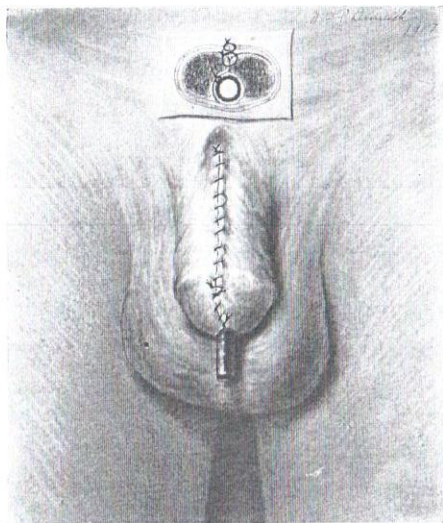


FIG. 14. THE OPERATION COMPLETED

The two outer edges of the original incision were easily brought together in the midline making a penis and glans almost normal in appearance.

Suprapubic drainage has been entirely satisfactory. The plastic operation has healed everywhere except at the root of the penis where tissues were not closed. Urethral suppuration has ceased. General condition excellent. January 10, 1921: Suprapubic drainage continued, occasionally patient is able to void through the new formed urethra and has

good control. January 30: Urine escapes from a small fistula at the base of the penis. Filiforms show a stricture or division of the urethra

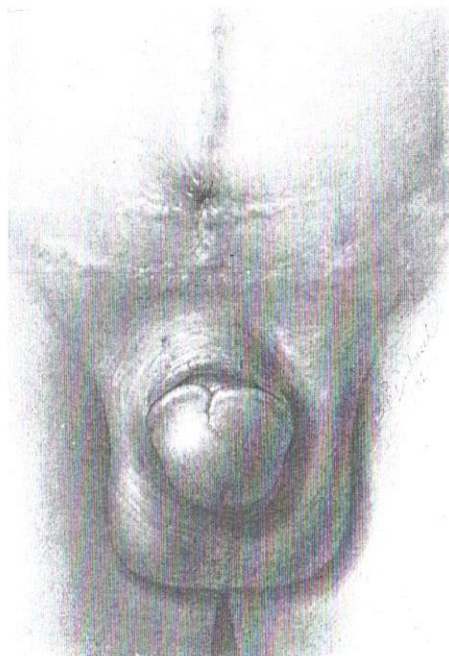

FIG. 15. RESULT SEVEN MONTHS AFTER CURE OF EPISPADIAS

No fistula, no stricture, perfect urinary control, sexual powers normal

about an inch from the new meatus. After some difficulty filiforms and followers are passed and urethra is well dilated. February 11: Sounds

again passed through the new urethra. Suprapubic sinus completely closed. Patient voids urine freely, good stream and has complete control. February 15: Excellent condition maintained, further dilatation carried out. Patient able to void normally about every four hours. Fistula at base of penis almost healed. No. 22F sound passed

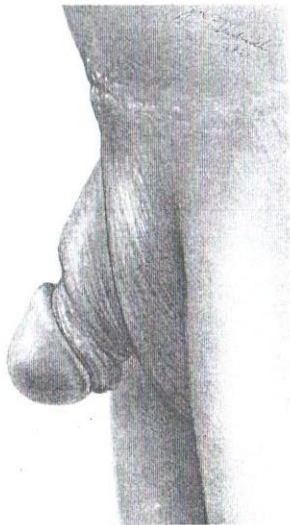


FIG. 16. CONDITION SEVEN MONTHS AFTER OPERATION

with ease. General condition excellent. Patient has complete urinary control. On erection the penis is straight, upward curvature has practically disappeared. Patient is discharged.

May 17, 1921: Patient returns for observation. He is able to retain urine all night and for normal intervals during the day. He drinks water in considerable quantity and passes as much as 300 cc. at a time.

He has complete control and even when the desire to urinate is strong he is able to hold urine until he can walk to a convenient place to void. Libido, erections and sexual powers are quite normal. Intercourse frequent and entirely satisfactory. Ejaculations apparently normal in every respect.

Examination: The condition present is shown in the accompanying drawings (figs. 15 and 16). As seen here, the glans is normal in appearance with the exception of a small scar along the corona in the median line above. The prepuce is redundant on each side beneath the glans. The dorsum has been completely restored and the corpora cavernosa approximated in their proper position in front of the urethra, which lies along the inferior surface of the penis. The patient passes urine freely in large stream, has perfect control and urine is sterile. He states that the organ on erection is about 4 inches in length and coitus normal.

Comment: The result obtained here is to be considered quite ideal and justifies us in feeling that at last a satisfactory procedure has been discovered for the complete cure of these severe deformities associated with the most distressing condition, incontinence of urine.

In another case, operated upon previously, a similar procedure was carried out. This case is as follows:

Case 2. No. 7677 BUI, L. H. Age nine years. Admitted April 23, 1919.

Complaint: Deformity of penis. Incontinence of urine.

Family history: Negative. No history of miscarriages or deformities.

Past history: Negative with the exception of deformity of the genitalia which has been present since birth and which has always been associated with incontinence of urine, both by day and by night. Urine escapes without his knowledge and is not associated with any pain or discomfort in the urethra, bladder or kidneys. He has otherwise been entirely well.

Examination: Patient is a well-developed, well-nourished boy of nine years, weighing 60 pounds. He is fairly robust in appearance and the heart, lungs and abdomen are quite negative. Suprapubic region negative. Groins negative.

Genitalia: Scrotum and testicles are apparently normal and well-developed. Penis presents an extreme degree of epispadias. Penis: the typical picture of complete epispadias is present with a continued

leakage of urine which constantly escapes through the trough-like urethra. The superior gutter-like depression does not completely divide the glans penis and the corpora cavernosa are coapted for a short distance beneath the gutter which is deeper than in the case described in my operation for the cure of epispadias. The foreskin, as usual, lies in loose folds on each side of the glans penis. When the penis is drawn outward and downward the deeper urethra appears as a deep pocket with a hooklike fold of mucous membrane above. Instruments are easily passed into the bladder and there is no constriction or obstruction of any sort but the urethra is apparently dilated in the region of the deep urethra. Plain X-ray shows a wide separation of the symphysis pubis, but on examination no failure of coaptation is made out. Cystogram with bladder filled with thorium shows a pear-shaped bladder with a funnel-like neck. Urine: cloudy, acid reaction, microscopically numerous short bacilli, but no pus.

Comment: The surgical problem presented here was first incontinence and secondly epispadias. Examination seems to indicate a dilated or relaxed vesical orifice; it seems wise, therefore, first to carry out an exploratory suprapubic cystostomy with the hope of curing the incontinence and then in a subsequent operation to attack the epispadias.

May 9, 1919: Operation, Young. Nitrous-oxide, oxygen, ether. Suprapubic cystostomy. Plastic operation to restore vesical sphincter and cure incontinence, suprapubic drainage. Division of glandular urethra preliminary to a subsequent epispadias operation. The bladder was opened in the median line extraperitoneally and an excellent view was obtained. Instead of the usual tight prostatic orifice, the urethra was widely open and it was easy to see the verumontanum in the floor of the urethra, the posterior urethra being a funnel-shaped part of the bladder. Examination failed to show any evidence of internal sphincter, examination with the finger in the urethra seemed to indicate that the external sphincter was present and the operator, therefore, decided to direct his attention to the internal orifice and sphincter. Accordingly the urethra was divided in the median line anteriorly as far as the triangular ligament and external sphincter and then with scissors a wedge-shaped strip was excised on each side including a part of the anterior wall of the bladder and of the roof of the dilated prostatic urethra on each side. This excision of tissue extended down to the region of the triangular ligament and external sphincter. Examination showed that there was muscle present on each side whereas in the

median line the tissues had been largely fibrous external to the urethral mucous membrane. The cut edges were approximated with interrupted heavy chromicized catgut sutures which did not include the mucous membrane and were tied externally. A catheter which had been passed through the urethra into the bladder was then removed, and examination showed that the internal urethral orifice was tight and the tissues well approximated. The anterior wall of the bladder was closed by a continuous chromicized catgut suture which did not include the mucosa. A drainage tube was brought out of the upper angle of the vesical wound, no urethral drainage being provided. The suprapubic wound was then closed with interrupted silver wire sutures for muscles and skin with a small gauze prevesical drain. The gutter along the roof of the penis which did not extend through the glans penis was then prolonged by dividing the glans deeply thus bringing the gutter to the end of the penis preparatory to a subsequent operation.

Remark: At operation a good view of the anterior bladder was obtained, the trigone and ureters seemed about normal but the vesical orifice was so greatly dilated that the verumontanum was easily seen and the tissues of the roof of the posterior urethra were very thin and fibrous. It would seem, therefore, that there had been failure of coaptation of the muscular and probably glandular structures of the prostatic and vesical neck, in other words that the foetal defect which produces the epispadias extends back to the bladder. Operation was very successful in producing a tight vesical orifice.

Convalescence, May 15: Suprapubic drainage has been successful but the patient has complained of much pain in the region of the bladder. May 18: Davis suction apparatus applied, condition satisfactory, much less pain. May 26: Vesical drainage continued. The incision in the dorsum of glans is kept open by adhesive so as to allow the mucous membrane to grow along the line of incision and form a gutter continuous with that between the corpora cavernosa. No urine escapes through the penis. May 30: Suprapubic catheter removed, patient voided a small amount of urine through the penis at intervals. June 4: Suprapubic fistula has been closed completely for three days, patient voiding at intervals through the urethra. June 8: Urine contains pus and bacilli. Vesical instillations of mercurochrome 1 per cent twice daily begun. June 12: Patient voids urine at intervals and apparently has good control, only occasionally slight lack of control.

June 14: Patient now can retain urine for three to four hours, voids freely and has good control. Urine still cloudy with bacilli and pus.

Patient is discharged in excellent condition. To return next year for epispadias operation.

Second admission, May 2, 1920: Patient's condition has improved during the past year. He is now able to retain urine for five to six hours, has no incontinence at night or during the day, voids freely, good stream. The epispadias is still present, the furrow in the glans is deeper than before previous operation but not sufficiently deep. Corpora cavernosa are partly separated by the urethral trough but are partly attached to each other beneath. Urine is acid in reaction. Sp. gr. 1016, free from infection and pus. General condition excellent. No suprapubic scar. Previous operation has been entirely successful in curing the incontinence.

May 5, 1920: Operation, Young. Nitrous-oxide, oxygen, ether. Perineal urethrotomy, insertion of catheter into the bladder for drainage. Plastic operation to cure the epispadias, following author's technique (16).

Before carrying out the plastic to cure epispadias the urethra was opened in the perineum and a catheter inserted in the bladder and fastened to the skin with sutures so as to provide drainage and avoid urinary soiling of plastic operation.

In this case the urethral trough was deeper than in the previous cases, the corpora cavernosa were not quite completely separated and the furrow in the glans was shallow. First an incision was made in the midline above the base of the penis and by blunt dissection the deeper portion of the bulbous urethra was exposed and freed in front and on each side, thus furnishing a deep tube about an inch in length. In front of this point the urethra was in the form of a gutter along the superior surface of the penis. Incisions were then made on each side to the median line leaving an abundance of tissue adjacent to the gutter to form a new urethra of ample size. On the right side the incision was carried deeply through the tissue of the glans until near the posterior surface. On the left side the incision in the glans was only extended about half this distance. Glans penis was then divided into two halves. On the right side the dissection along the gutter was continued backward until the corpora cavernosa had been completely separated. On the left side the mucous membrane was left attached to the inner surface of the left corpus cavernosum to insure a good blood supply but the edge was sufficiently freed to be drawn over the catheter and sutured to the opposite side to form a spacious new urethra. A continuous chromicized catgut mattress suture (Cushing type) was used, an excellent

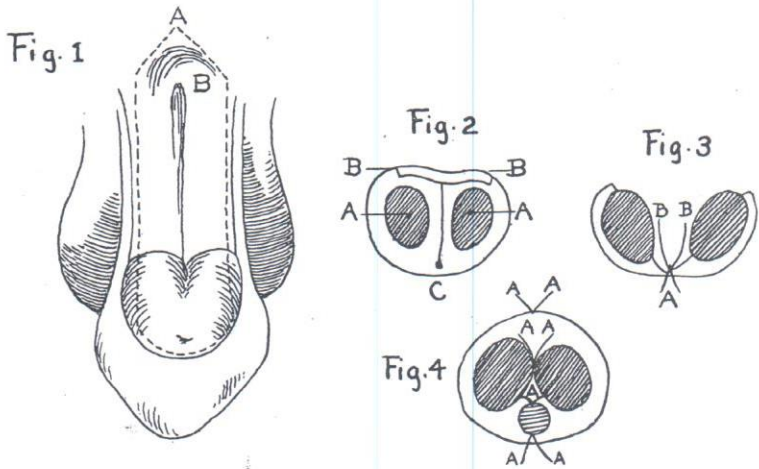
approximation and inversion of the skin obtained, a second line of stitches to reinforce the first line of sutures was used, also continuous chromicized catgut. The corpora cavernosa were then drawn together above the new formed urethra which had been depressed into its proper position along the inferior surface of the penis. The divided glans penis was then approximated in front of the urethra which then presented a normal appearance along the inferior surface everywhere and a fairly normal looking glans was produced. The skin along the dorsum was then drawn together with a continuous chromicized catgut suture which extended back almost to the root of the penis, a small area being left open near the symphysis pubis for escape of serum. The catheter around which had been placed was then removed. Patient stood operation well and was in good condition at end of operation. The plastic result was apparently very satisfactory.

Convalescence, May 8: Patient has been comfortable. Urinary drainage through perineal catheter quite successful. May 11: The scrotum has become very edematous and red. May 12: Scrotum less swollen and condition is improved. May 15: Condition improved, healing of plastic satisfactory, except in region of glans which is slightly broken down. Scrotal swelling completely subsided. May 22: Catheter removed. Sutured wounds healing satisfactorily. May 26: Perineal wound almost closed, patient voids urine at intervals in good stream through the new formed urethra. June 9: It is now thirty days since operation. Wound has healed well. Urethra is satisfactory and lies on the inferior surface of the penis. Meatus is small. Penis is somewhat irregular and not entirely normal in appearance but the functional result is good. Patient has complete urinary control, voids freely at intervals of four hours. Urine is sterile and free from pus. Patient has had no instruments passed. General condition is excellent. Patient is discharged, to return subsequently for examination.

May 15, 1921: The patient's father writes that the boy is able to retain urine for four hours during the day and all night. There is no fistula present and no instruments have been passed since the operation. His general health is very good.

Comment: The results obtained in this case have been almost ideal, in that there was not only restoration to normal position of the external urethra (beneath the corpora cavernosa and glans), but also a complete cure of the incontinence. The technique adopted for the repair of the vesical neck and the cure of the epispadias were completely justified.

In commenting upon the procedure too much stress cannot be laid upon the great importance of excising sufficient mucous membrane and all other tissues along the roof of the urethra so that when the lateral stitches are drawn together, a sufficiently



Cantwell's Method.

FIG. 17

1. The dorsum of the penis in a complete epispadias. *A*, the dotted line represents the line of incision for urethral flap. *B*, the infundibulum or opening into the bladder.
2. A transverse section of an epispadias. *A-A*, the corpora cavernosa. *B-B*, a transverse section of flap composed of urethra, and, if necessary, the remains of the corpus spongiosum. *C*, the line of incision between the corpora cavernosa down to the skin on the under surface of penis.
3. A transverse section of an epispadias showing the cavernous bodies separated. The urethral flap (*B-B*) laid on the gutter and a retention suture (*A*) in place.
4. Transverse section of penis after operation showing the sutures (*A, A, A, A*) in place.

tight vesical orifice will be obtained. What we require is a tonically closed orifice which will be opened only by contracture of the trigone in the voluntary voiding of urine. The procedure by which normal micturition is accomplished, which was just

described by the author in 1919, has been presented again in extenso by Dr. M. B. Wesson, (17) who has furnished, by most careful embryological studies, the proof of the relation between the trigone and the vesical sphincter in opening the vesical neck to allow the escape of urine, and by Young and Wesson (18). The process of micturition is not (as so long held) merely an inhibitory dilatation of the internal sphincter or vesical neck with expulsion of urine by vesical contracture, but a definite pulling open of the vesical orifice by muscular contracture of the trigone. In both of these cases, the trigone, from non-use since birth was atrophic and the musculature less definite than normal. These cases seem to show, however, from the complete restoration to normal micturition which has been obtained, that trigonal muscle after years of non-use can functionate normally when the vesical neck has been restored to a condition of normal closure by a plastic operation, as carried out in the radical operation above outlined.

It may be well here to refer again to the author's technique for the cure of penile epispadias, which was presented in 1917 (16) and which has now been employed in five cases with excellent results. In no case has there been any sloughing of the transplanted mucous membrane which forms the new urethra, as has been reported after Cantwell's operation (fig. 17). The plan of leaving skin tube attached to one corpus cavernosum so as to insure proper blood supply and also to aid contracture and subsequent retention to its position beneath the corpora cavernosa on the inferior surface of the penis has been completely justified, and in all of these cases has furnished a technique by which it has been possible to completely cure the defect in one operation and to produce a practically normal penis.

CONCLUSIONS

1. Simple epispadias can be repaired very satisfactorily by a technique described by the author in 1917 (16).
2. In cases associated with incontinence of urine there is a muscular defect along the roof of the deep urethra associated

with dilatation of the vesical orifice and the urethra in the region of the external sphincter.

3. To obtain a radical cure of the incontinence and restoration to normal urination the plan proposed, namely, to excise the superabundant roof of the urethra and restore the vesical neck and external sphincter by sutures, is justified by a report of two cases in which perfect results have been obtained.

My thanks are due to Wm. P. Didusch for much assistance and excellent drawings.

REFERENCES

- (1) BERRY HART: Transactions of the Edinburgh Obstetrical Soc., 1900-1901, xxvi, 305.
- (2) BALLANTYNE: So-called epispadias in woman, with an illustrative case. Edinburgh Hospital Reports, 1896, iv.
- (3) NOVÉ-JOSSERRAND AND COTTE: L'Epispadias féminin et son Traitement chirurgical. Revue de Gynecologie et de Chirurgie abdominale, December 10, 1907.
- (4) MAKINS, G. H.: Clinical lecture on the treatment of epispadias in the female and hypospadias in the male. Lancet, London, 1894, ii, 1140.
- (5) GOEBELL: Zur operativen Beseitigung der angeborenen Incontinentia vesicae. Zeitschrift f. gynakologische Urologie, bd. 2, No. 4, 1910.
- (6) HACKENBRUCH: Medizinische Klinik, No. 31, 1909, viii, 1.
- (7) MAYERSBACH: Die weibliche Epispadie und ihre Behandlung. Wiener Klin. Wochenschrift, No. 52, 1908.
- (8) STILES, H. J.: Epispadias in the female and its surgical treatment. Surgery, Gynecology and Obstetrics, 1911, xiii.
- (9) STEINER, FR.: Operative Behandlung der Epispadiasis und der angeborenen Blasenspalte—Archiv für Clinische Chirurgie, xv, 1873, p. 369.
- (10) PAGE, H. W.: Lancet, London, 1898, Nov. 5.
- (11) STETTINER, HUGO: Egebn d. deutsch Gesellsch f. Chir. 1914, xliii.
- (12) STOECKEL, W.: Die Operative Therapie bei Insuffizienz des Blasenschlussmuskels mit Demonstrationen. Zentralblaf. Gynäk., 1920, xliiv, p. 786.
- (13) BARNEY, J. D.: Epispadias in the Male. Surgery, Gynecology and Obstetrics, xxiii, 1916, p. 594.
- (14) YOUNG, H. H.: Suture of urethra and vesical sphincter for the cure of incontinence of urine with report of a case. Trans. South. Surg. & Gyn. Assoc., 1908, xx, 210.
- (15) YOUNG, H. H.: An operation for the cure of incontinence of urine. Surg., Gyn. and Obstet., January, 1919, p. 84.
- (16) YOUNG, H. H.: New operation for epispadias. Jour. Urol., ii, no. 3, 1915.
- (17) WESSON, M. B.: Anatomical, embryological and physiological studies of the trigone and neck of the bladder. Jour. Urol., iv, no. 3, June 1920.
- (18) YOUNG, H. H., AND WESSON, M. B. The anatomy and surgery of the trigone. Archives of Surgery, July, 1921, iii, 1-37.