

IE CUMSTON

seldom, and always with ease

ention was given to the opera-  
urgeons in the middle of the  
ave read on the subject in the  
shed at the time, I unhesi-  
illed operators employed the  
tion and that their results

## THE EMPLOYMENT OF THE HIGH FREQUENCY CURRENT FOR THE EXTRACTION OF CALCULI INCARCERATED IN THE LOWER END OF THE URETER

HUGH HAMPTON YOUNG

*From the James Buchanan Brady Urological Institute, Baltimore, Maryland*

Various methods have been proposed for the extraction of calculi in the terminal intravesical portion of the ureter. In 1903<sup>1</sup> the writer made an exhaustive study, and presented one case in which he was able to extract a calculus incarcerated in the lower end of the ureter by means of a ureteral catheter, and also mentioned cases in which stones had been removed from this portion of the ureter by suprapubic cystotomy. Since this time several articles have appeared detailing various cases in which, by means of dilating instruments, forceps or scissors, calculi have been extracted from the lower end of the ureter intravesically. Bransford Lewis has been one of the most frequent contributors on this subject.

The technique which is presented herewith consists in the employment of the high frequency spark to incise the mucous membrane covering the incarcerated calculus, thus enlarging the ureteral orifice to a degree sufficient to permit its passage into the bladder.

*Case 1.* No. 4390, aged 29, was admitted May 22, 1915, complaining of recurring attacks of colicky pain in the lower portion of the abdomen on the left side. Ureteral catheterization had been carried out elsewhere in December, 1914, following which he passed a small stone.

On cystoscopic examination there was marked enlargement of the left corner of the trigone and left ureteral ridge, both of which were very prominent. The picture at once suggested an incarcerated calculus in the intravesical and intramural portions of the ureter, notwith-

<sup>1</sup>The surgery of the lower ureter. *Annals of Surgery*, 1903, xxxvii, p. 668.

standing the fact that the plain X-ray revealed no shadow in this region. Attempts to pass a ureteral catheter were unsuccessful and it occurred to the writer that it would be possible to enlarge the ureteral orifice by fulguration of the mucosa which was stretched tensely over the stone. This was accordingly done and a linear burn made, starting at the ureteral orifice and extending along the line of the ureteral ridge for a distance of about 1.5 cm. Following fulguration there was some vesical

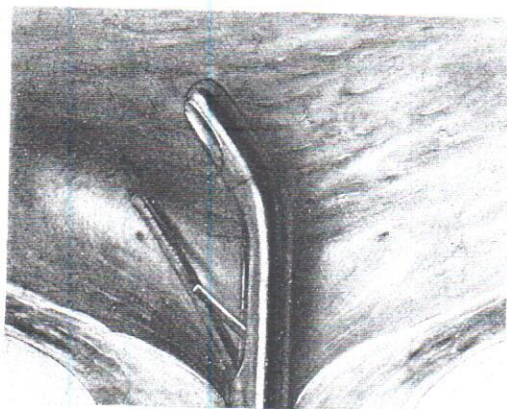


FIG. 1. SCHEMATIC VIEW OF BLADDER

Showing marked bulging of intramural portion of ureter due to incarcerated stone. Cystoscope and fulgurating wire in place.

irritation but no definite pain in the kidney, ureter or testicle. Three days after the treatment there developed considerable urinary urgency, frequency and pain at the end of urination. These symptoms continued for two days, when the patient passed through the urethra a calculus, measuring 4 by 6 by 8 mm. This was accompanied by slight hemorrhage, the first he had noticed. There was no hematuria subsequently and the pain which had been present in the region of the kidney ceased. The patient was discharged eleven days after fulguration, free from symptoms and able to retain urine for eight hours.

revealed no shadow in this region. Attempts were unsuccessful and it occurred to enlarge the ureteral orifice by stretching tensely over the stone. A linear burn made, starting at the line of the ureteral ridge for a fulguration there was some vesical



VIEW OF BLADDER

portion of ureter due to incarceration in place.

kidney, ureter or testicle. Three days after considerable urinary urgency, retention. These symptoms continued through the urethra a calculus was accompanied by slight hematuria. There was no hematuria subsequently the region of the kidney ceased. The patient was free from symptoms eight hours.

*Case 2.* No. 5411, aged 36, was admitted October 3, 1916, complaining of stone in the right ureter. He had had intermittent attacks of pain for almost three years, the pain being typical of ureteral colic, beginning in the right side and radiating into the right groin and testicle, and was accompanied by occasional hematuria.

The X-ray examination revealed a large ureteral calculus in the terminal portion of the ureter. On cystoscopy, the right corner of the trigone and right ureteral ridge were considerably enlarged and oedematous. The ureteral orifice was small and round, and from it was seen protruding a portion of a black irregular calculus. A ureteral catheter was passed and an unsuccessful attempt made to dislodge the stone. The high frequency was then directed to the mucous membrane and a linear burn 1 cm. in length made, beginning at the orifice and extending upward to the limit of the prominence caused by the calculus. On the fourth day after fulguration, X-ray examination showed the stone in the same position. The patient had had considerable vesical disturbance, with retention of urine on three occasions. On the sixth day, the stone was passed "without the slightest pain," according to letter from the patient. He was heard from nine months later at which time he was free from symptoms.

*Case 3.* No. 3935, aged 24, was first admitted May 16, 1914, complaining of intermittent attacks of pain in the back and testicles. X-ray examination revealed the shadow of a stone in the right ureter just below the uretero-pelvic junction; the remainder of the examination was quite negative. On May 29, 1914, a lumbar uretero-lithotomy was performed and the calculus removed. The patient was practically free from symptoms until September, 1916, when he began having attacks of renal colic, on the left side, the pain radiating into the testicle. These attacks were always followed by the appearance of blood in the urine. On X-ray examination a definite shadow was seen in the region of the lower end of the ureter. On cystoscopy, December 30, 1916, the left ureteral orifice was apparently normal and the ureteral ridge was quite prominent, the mucous membrane bulging, as shown in the accompanying illustration. A ureteral bougie armed with a waxed tip was passed into the left ureteral orifice and a definite scratch obtained. A linear burn 1 cm. in length was made, extending from the ureteral orifice upward and outward in the direction of the ureteral ridge over the prominence produced by the calculus. January 8, 1917, the patient passed a stone measuring 1 cm. in length and 4 mm. in diameter, slightly rough and composed entirely of calcium oxalate. On cysto-

scopy, February 17, 1917, the left ureteral orifice was somewhat elongated and of irregular shape but functioned normally. The right ureteral orifice was circular, pinpoint in character, evidently slightly constricted, and the ejection of urine was accompanied by a slight ballooming above it.

#### CONCLUSIONS

The employment of the high frequency current in cases of calculus, incarcerated in the intramural and intravesical portions of the ureter, is successful in enlarging the orifice sufficient to permit its passage. Furthermore this operation is simple, can be carried out without anaesthesia, and does not produce more than slight hemorrhage.