

An Animal Model for Cochlear Implants

Erika A. Kretzmer, BS; Noah E. Meltzer, MD; Charles-André Haenggeli, MD; David K. Ryugo, PhD

Objective: To test the feasibility of using the deaf white cat model of early-onset deafness. We studied the neuronal effects of prosthetic intervention with a clinical, “off-the-shelf” multichannel cochlear implant.

Methods: We placed cochlear implants in 5 deaf white kittens at age 12 and 24 weeks. The devices were activated and stimulated in the laboratory using a clinical speech processor programmed with a high-resolution continuous interleaved sampling (CIS) strategy for 8 to 24 weeks. Stimulus parameters were guided by electrically evoked brainstem responses and intracochlear-evoked potentials. Kittens were assessed with respect to their tolerance and general behavior in response to speech, music, and environmental sounds.

Results: Surgical complications were minimal, and kittens tolerated the experimental procedures well. Subjects were able to detect and respond to a specific sound

played from a computer speaker. Electrophysiologic responses were reliably attainable and showed consistency with observed behavioral responses to sound. This experimental paradigm, using clinical devices, can be used in a practical research setting in cats.

Conclusions: Deafness and other variations in neural activity result in many distinct changes to the central auditory pathways. Animal models will facilitate assessment of the reversibility of deafness-associated changes at the level of the neuron and its connections. Our observations of the feasibility of using clinical devices in animal models will enable us to simulate clinical conditions in addressing questions about the effects of “replacement” activity on the structure and function within the central auditory pathways in deafness.

Arch Otolaryngol Head Neck Surg. 2004;130:499-508

IT HAS LONG BEEN KNOWN THAT SENSORY deprivation in the developing animal has a profound effect on the maturation of brain structure and function. For example, covering one eye of a kitten causes the cortical projections of the uncovered eye to expand into the covered eye’s territory.¹ When the eye is uncovered, the visual cortex remains unresponsive, and the animal is functionally blind in the deprived eye. These results resemble amblyopia caused by pathologic monocular occlusion in human infants, and these observations led to early intervention to prevent permanent amblyopia in these infants (eg, see von Noorden²). These and similar kinds of observations have generated the idea that there is a critical period during development when the central nervous system needs environmental stimulation.

Studies of a critical period in audition have been difficult because complete deafening procedures are irreversible, and simple occlusion does not

eliminate spontaneous activity in the auditory nerve. However, a crude form of activity can be restored in the completely silent auditory system with a cochlear implant. Clinical experience with cochlear implants suggests that there is a sensitive period for auditory development. Postlingually deafened adults have the best outcomes after cochlear implantation, presumably because their deafness occurred after the critical developmental period for spoken language. Prelingually deafened adults have great difficulty achieving acceptable aural communication skills. Among children, success is negatively correlated with age at implantation and duration of deafness. These observations imply that childhood deafness introduces developmental abnormalities into the central nervous system that are expressed as an inability to process auditory stimuli as an adult.^{3,4} Our research has been directed at understanding the changes that occur in the auditory system during the critical period for auditory development.

From the Center for Hearing Sciences, Departments of Neuroscience (Ms Kretzmer and Dr Ryugo) and Otolaryngology–Head and Neck Surgery (Drs Meltzer, Haenggeli, and Ryugo), Johns Hopkins University School of Medicine, Baltimore, Md. The authors have no relevant financial interest in this article.

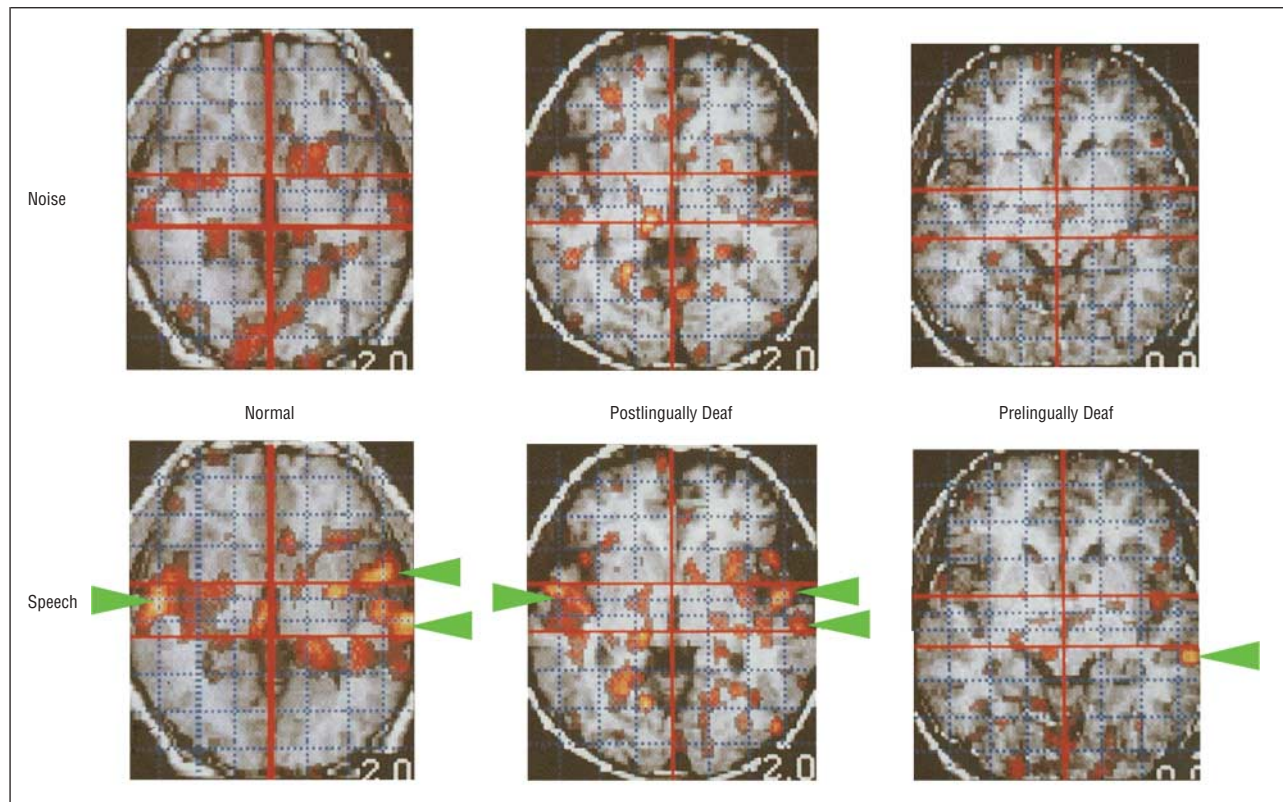


Figure 1. Positron emission tomographic scans comparing prelingually deaf with postlingually deaf human cochlear implant recipients. Two types of experimental auditory stimuli, noise and speech, were presented to subjects. Images were obtained in 3 categories of patients: normal, prelingually deaf, and postlingually deaf cochlear implant recipients. Speech produced prominent bilateral increases in cortical activity in the normal and postlingually deaf cochlear implant recipients, especially in auditory cortex (arrowheads). In prelingually deaf patients, only primary auditory cortex contralateral to the cochlear implant was significantly activated. Adapted from Figure 3 of Naito et al⁵ and reprinted with permission.

Cortical functional imaging techniques have demonstrated central auditory function in patients with cochlear implants. Positron emission tomography (PET) is a technique for detecting the location of positron-emitting radioisotopes within the subject. In the brain, metabolically active isotopes in the blood concentrate in regions of higher neural activity through autoregulation of regional cerebral blood flow (rCBF). Relative neural activity can thus be represented in a topographic color image that is usually overlaid on a higher-resolution image, such as one obtained from magnetic resonance imaging (MRI) or computed tomography. Normal-hearing subjects show increased rCBF during a listening task in both primary auditory cortex and secondary auditory cortical areas. Primary auditory cortex is involved in the processing of all sounds, whereas secondary auditory areas process increasingly more complex sounds, including speech. Postlingually deafened implant recipients show increases in primary and secondary auditory rCBF during implant use, similar to increases seen in normal-hearing subjects. In contrast, prelingually deafened patients generally have lower rCBF in auditory cortex during implant use, and increases in rCBF are restricted to primary auditory cortex contralateral to the implant (**Figure 1**).⁵⁻⁷ The implication may be that in the prelingually deaf patients, corticocortical connections between the primary auditory area and higher-ordered areas

were not established during early development. Moreover, the data suggest that these connections cannot be formed in the adult.

Interestingly, studies suggest that increased baseline auditory cortical activity occurs in prelingually deaf patients. This effect has been attributed to cross-modal cortical plasticity where one functional area (eg, visual cortex) is used to perform the function of another (eg, listening with imaginary lipreading).^{8,9} The underlying circuitry might involve a change in corticocortical connections or changes at lower levels of the auditory system.

Functional MRI, based on blood oxygenation level-dependent contrast, can reveal changes in cortical activity with greater spatial and temporal resolution than PET. Solutions to the technical challenges of functional MRI in cochlear implants are being developed that may ultimately allow a more detailed look at cortical function in cochlear implant recipients.¹⁰ Functional MRI studies comparing prelingually and postlingually deaf patients with cochlear implants have not been published. In addition, the resolution of available functional imaging techniques remains far below that required for detection of changes in cells and synapses. For this reason, animal models of congenital sensorineural deafness are critical to elucidate the central auditory consequences of deafness and cochlear implantation. One such animal is the deaf white cat.

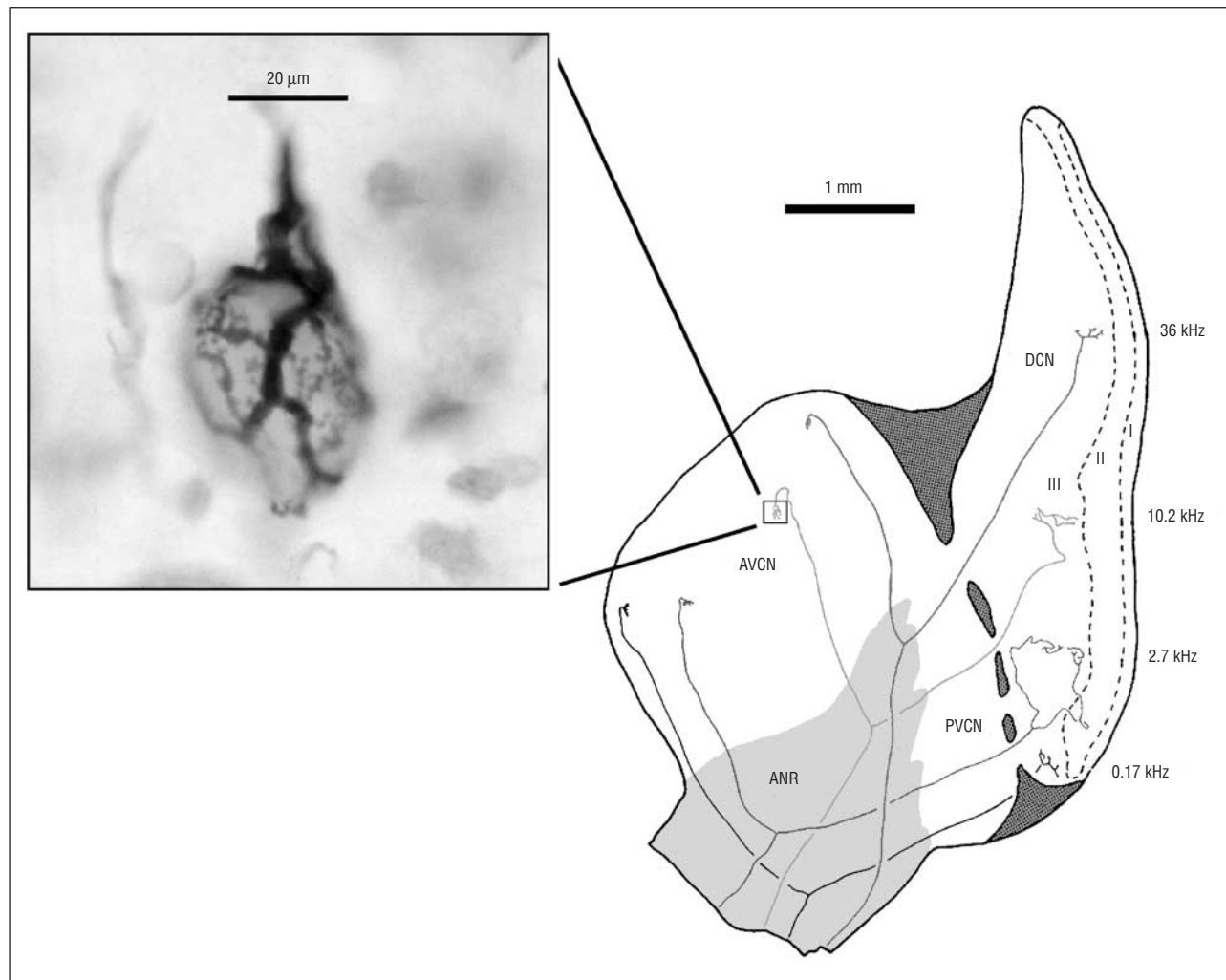


Figure 2. Auditory nerve fibers in the cat are arranged in an orderly pattern in the cochlear nucleus. Auditory nerve fibers enter the cochlear nucleus at the auditory nerve root and branch in a cochleotopic fashion.¹⁴ Four physiologically characterized and stained auditory nerve fibers are superimposed on a sagittal section of the cochlear nucleus. The fibers have a characteristic frequency of 0.17, 2.7, 10.2, and 36 kHz. They send an ascending branch to the anteroventral cochlear nucleus (AVCN) and a descending branch through the posteroventral cochlear nucleus (PVCN) to the dorsal cochlear nucleus (DCN). In the AVCN, each auditory nerve fiber forms a large terminal ending known as the endbulb of Held. A photograph (inset) of a horseradish peroxidase–stained endbulb shows the size and complexity of this structure and its close relationship with the postsynaptic cell. ANR indicates auditory nerve root. Adapted from Figure 9 of Ryugo and Parks¹⁵ and reprinted with permission.

ANIMAL MODELS

The Deaf White Cat

Deaf white cats have abnormal inner ear structure that results in complete sensorineural deafness from birth. The genetic cause of this deafness is unknown. Although hair cells are absent, spiral ganglion cells are generally present in young deaf cats, but these spiral ganglion cells progressively degenerate over the first few years of life.¹¹ In these cats, there is no detectable spontaneous activity in the auditory nerve.¹² The deaf white cat also has abnormal auditory cortical function, most likely due to sensorineural deafness.¹³

Klinke et al¹³ measured cortical activity with electrodes in deaf cats during electrical intracochlear stimulation of the auditory nerve. The researchers described decreased activity in congenitally deaf cats compared with cats deafened immediately before experimentation. Specifically, auditory association areas peripheral to pri-

mary auditory cortex were not active in congenitally deaf cats. This result suggests decreased corticocortical connectivity in cats with long-term deafness. The researchers also found an increase in cortical area activated by electrical stimulation in cats that wore cochlear implants and processors for several months. This observation suggests that auditory cortex is recruited for auditory processing after experience with the cochlear implant. It seems reasonable to hypothesize that significant morphologic changes in primary auditory cortex accompany the physiologic changes indicated by functional imaging in humans and cortical recordings in the deaf white cat. We are currently investigating the neuroanatomic correlates of these changes to determine whether they can be explained by changes in corticocortical connectivity.

Other structural abnormalities are found in the deaf white cat at lower levels of the auditory system, including the brainstem. Changes at these levels are likely to affect the auditory information received by the cortex. Specifically, research in our laboratory has identified

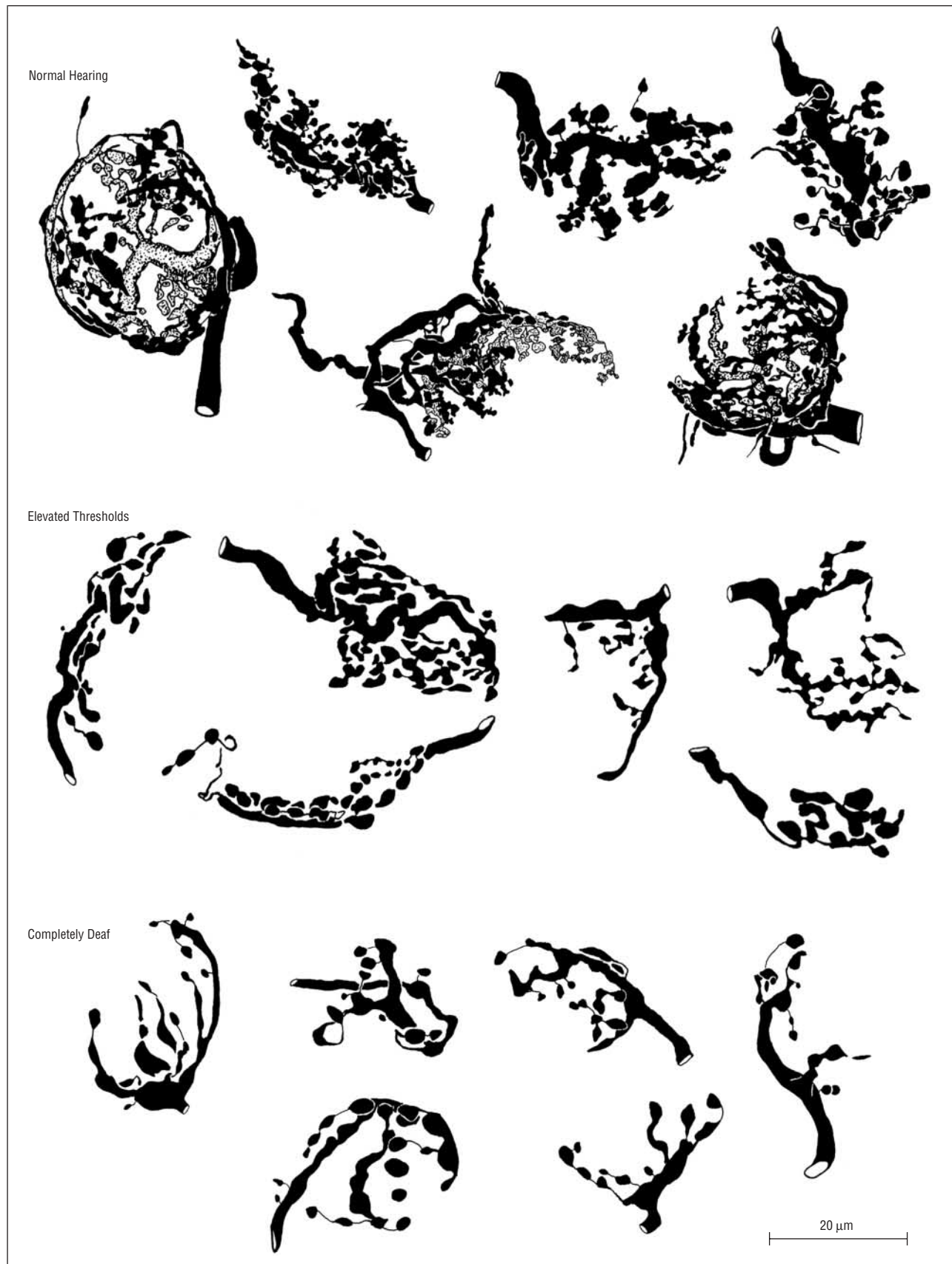


Figure 3. Endbulb (EB) structure is related to hearing sensitivity. These panels illustrate cat EBs that have been stained with horseradish peroxidase. Note that the EB covers a large proportion of the surface area of the postsynaptic cell. The EBs from normal-hearing cats are larger and exhibit more complex branching than those from deaf cats. Endbulbs from cats with intermediate hearing are intermediate in size and branching complexity. Adapted from Figure 10 of Ryugo et al¹⁷ and reprinted with permission.

changes in a unique presynaptic specialization, the endbulb of Held, which marks the termination of auditory nerve fibers in the cochlear nucleus (**Figure 2**).^{14,15} The unique shape of the endbulb and its location with respect to the postsynaptic cell suggest special functional importance. It is hypothesized that these endings ensure that neural activity is tightly coupled in time to acoustic events. Circuits that use endbulbs are thought to preserve rapid transients used in communication signals¹⁶ and are presumed to play a critical role in temporal processing, sound localization, and perception of pitch.

Deafness has a prominent effect on the structure of the endbulbs of Held. It appears that branching complexity in endbulbs is associated with hearing sensitivity. Endbulbs of normal-hearing cats are highly branched, whereas those in cats with progressively poorer hearing are smaller and less branched (**Figure 3**).¹⁷ Electron microscopy has revealed that the endbulbs of deaf cats contain far fewer synaptic vesicles and a slightly increased mitochondrial volume fraction. Furthermore, the synapses of deaf cats are significantly longer and flatter than those of hearing cats, and the postsynaptic material appears thicker (**Figure 4**).¹⁷ The postsynaptic cell seems to compensate for lack of activity by an up-regulation of synaptic area and an increase in material on the postsynaptic side. Such a response might ensure that the postsynaptic cell will not miss any transmitter released by the presynaptic ending. On the other hand, abnormalities such as reduced synaptic vesicle density suggest that endbulbs of deaf animals are less efficient at reproducing rapid signals from the auditory nerve.

The Shaker-2 Mouse

We examined the endbulbs in another congenitally deaf animal, the Shaker-2 mouse, to verify that the synaptic phenotype results from deafness and not the deaf white cat syndrome. The deafness of the Shaker-2 mouse is caused by a point mutation that affects myosin-15, a protein expressed primarily in stereocilia of the cochlear hair cell.¹⁸ The endbulbs of heterozygous (hearing) Shaker-2 mice resemble those of normal-hearing mice, cats, and other mammals. In contrast, endbulbs of homozygous (deaf) Shaker-2 mice are sparsely branched (**Figure 5**), resembling those of the deaf white cats. At the electron-microscopic level, clear differences in synaptic structure are apparent in affected mice. The hearing mice have distinct punctate synapses, whereas the mutant deaf mice have larger synapses. In size and distribution of the postsynaptic densities, deaf animals have hypertrophied synapses.¹⁸ Because cats and mice are not closely related, and because the underlying cause of deafness appears different, we propose that these abnormalities are due to deafness.

METHODS

COCHLEAR IMPLANTS

The effects of congenital sensorineural hearing loss on neural structure was explored using miniaturized cochlear implants

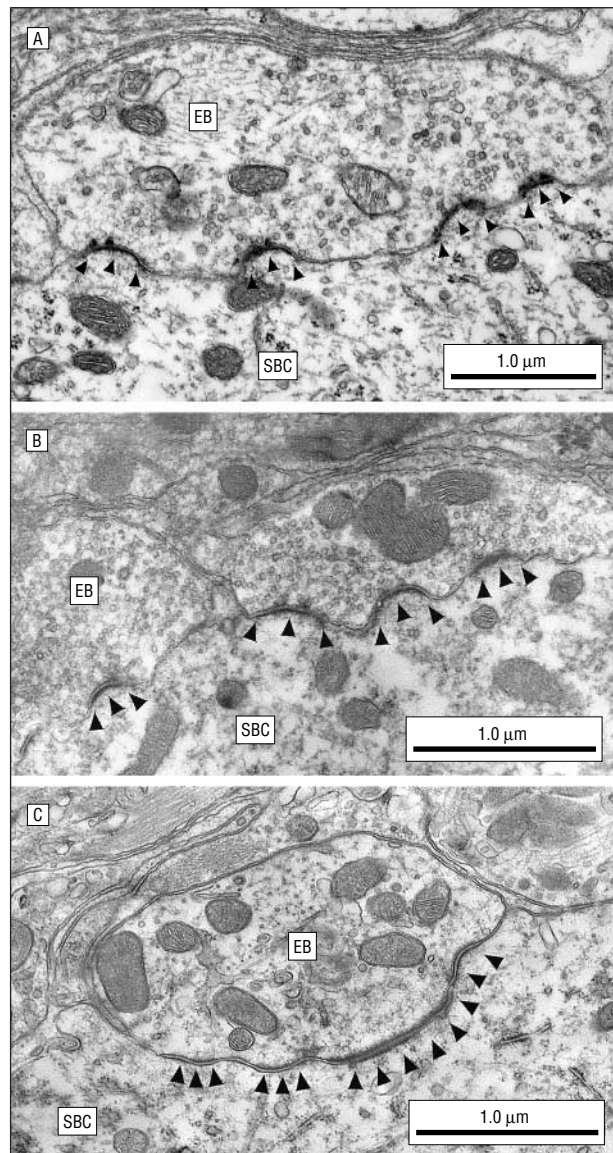


Figure 4. Electron micrographs reveal ultrastructural differences between endbulbs (EBs) from cats with different levels of hearing (A, normal; B, partially deaf; C, deaf). All EBs exhibit a complement of mitochondria, synaptic vesicles, and synaptic structures within the cytosol. Note the presynaptic vesicles and asymmetric membrane thickenings characterized by the postsynaptic densities (arrowheads) of the spherical bushy cell (SBC). Normal-hearing and hard-of-hearing cats exhibit EBs that are similar in appearance, marked especially by the pronounced curvature of the postsynaptic density. Deaf cats, however, have EBs with decreased numbers of synaptic vesicles and associated hypertrophied postsynaptic densities. Adapted from Figure 11 of Ryugo et al¹⁷ and reprinted with permission.

manufactured (and donated) by Advanced Bionics Corporation (Sylmar, Calif) to restore hearing in 3- and 6-month-old congenitally deaf white kittens. Four devices were Clarion II high-focus implants, manufactured with a smaller 6-electrode array for use in cats. This device can be controlled using a speech processor identical to that used with human patients or through a programmable interface for specialized applications. Features of this implant include simultaneous stimulation and recording from the implant electrodes, a biphasic pulse width of 21.6 microseconds, and use of the smaller, lighter, “behind the ear” processor that can be carried by small kittens.

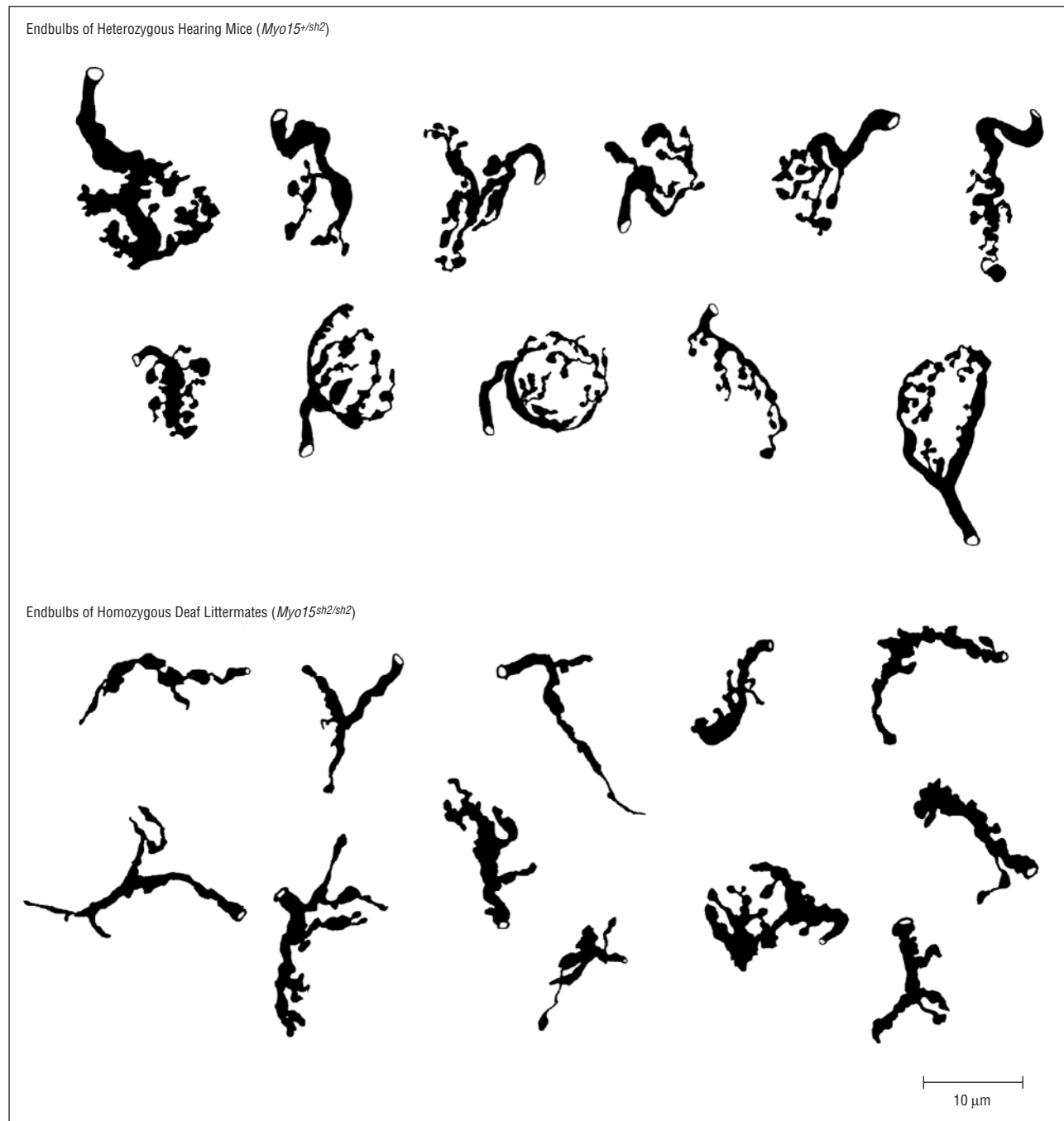


Figure 5. Drawing-tube reconstructions of endbulbs (EBs) from the Shaker mouse illustrate differences in EB structure associated with deafness. The EBs from deaf mice are smaller and less branched than those from hearing mice. The structure of these EBs resembles that of deaf and hearing cats, respectively. Collectively, the cat and mouse data suggest that EBs are highly reactive to the presence or absence of sound. Adapted from Figure 9 of Limb and Ryugo¹⁸ and reprinted with permission.

PROCEDURE

Our surgical technique was modeled after that used in human patients. We fixed the receiver on the animal's skull with sutures anchored through holes drilled in the orbital ridge and modified the surgical approach to the round window to accommodate the anatomy of the cat. The sutures were reinforced by a fibrous capsule of tissue that formed following surgery. One animal became infected around the receiver, and the experiment had to be terminated after only 2 months of stimulation, perhaps in part due to violation of the frontal sinus during receiver fixation.

An important consideration in cochlear implant surgery is avoiding the facial nerve in the approach to the cochlea. The facial nerve exits the temporal bone through the stylomastoid foramen, which in the cat is a small fenestration in the bulla a few millimeters posterior to the external auditory canal.¹⁹ Injury to the facial nerve, quantified by impaired outer eyelid functioning, was observed in 1 animal. Morbidity caused by this damage was insignificant because the cat's nictitating membrane, which receives motor and sensory innervation from the trigeminal nerve, moistens and protects the cornea in the absence of outer eyelid movement.

Electrode array position was confirmed with plain-film radiography after surgery (**Figure 6**). Typically, 5 or 6 electrodes were placed within the cochlea at an estimated depth of 12 to 15 mm from the round window opening. The cats were allowed to heal for 10 to 14 days prior to processor activation.

The implant was programmed in a fashion similar to that used at The Listening Center at Johns Hopkins Hospital for prelingual human infants. The goal of an initial programming session was to define the parameters of the continuous interleaved sampling program strategy (active electrodes and corresponding maximum comfortable current levels [M-levels]) that would be used in the speech processor for the individual kitten. Because verbal communication was impossible, we used behavioral cues such as pupil dilation, pinna movements, tail flicks, pinna flattening, and escape maneuvers to determine threshold and maximum levels for each functional electrode. Responses generally occurred in the above sequence in response to increased current levels, although pupil dilation was observed only in naive kittens on their first day of stimulation.

Electrodes that did not elicit these behaviors, or that resulted in involuntary muscle movements as the first response, were turned off. Frequently, electrodes with very high impedance could not be driven to produce effective stimuli. A series of intracochlear-evoked potentials was recorded for each electrode using the Clarion II devices. Most functioning electrodes displayed a neural response following the stimulus artifact in this measure (**Figure 7**). Four to 6 monopolar electrodes were activated for each cat.

After speech processor activation, the cats spent 7 hours per weekday in the laboratory wearing the magnetic headpiece transmitter and processor backpack (**Figure 8**). Significantly, the cats tolerated the magnetic headpiece when the implant was functioning. Minimal restraining devices, such as large collars, were needed for some animals. Cats with implants in place were housed together while wearing the processor without difficulty. They were observed to shake the headpiece off when the batteries were depleted or the device was disconnected.

RESULTS

After a brief training period, the cats responded to a complex sound that was followed by a special food reward. This response included arousal from sleep, pinna movements, vocalization, movement to the door of the cage, and attention to humans in the room. Such behaviors were not reliably observed following other sounds. Similar behavior can be elicited in deaf cats using a hand signal in place of a sound. We excluded the possibility that the cat was responding to a visual cue by recording the sound and playing it from a laptop computer hidden from the cat's view. This and other sounds were played by an unfamiliar experimenter and by visitors to the laboratory. Only the trained sound could elicit these behaviors in the cats. This sound was used daily to confirm that the cat was receiving stimulation.

Finally, we recorded electrically evoked auditory brainstem responses (EABRs) from some of the animals. The EABR waveforms recorded from our congenitally deaf cats with implants had the same number of peaks as those of normal-hearing cats that were

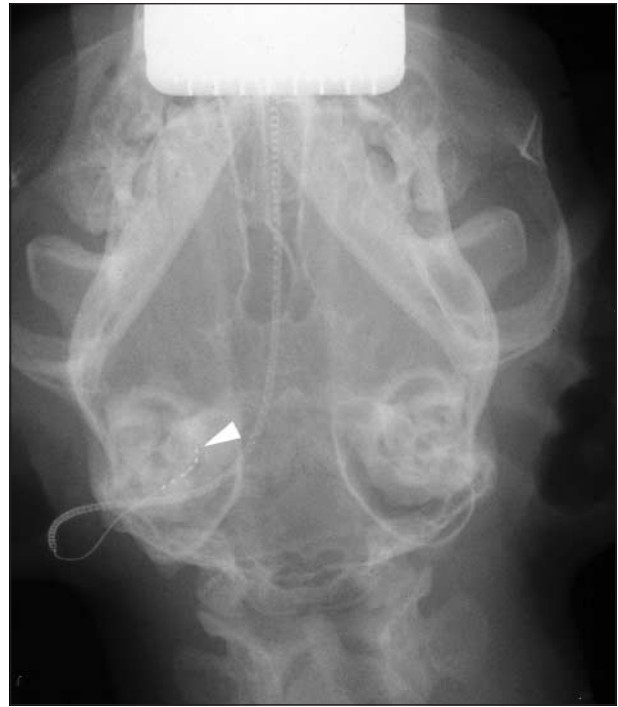

Figure 6. A radiograph of a cat with a cochlear implant shows the 6 electrode contacts (electrode 1 at white arrowhead) within the cochlea. The sixth electrode lies just inside the round window.

deafened and immediately subjected to electrical stimulation (**Figure 9**).²⁰ This measure was an additional verification that the central auditory system was stimulated in these cats. One important difference emerged, however, when the latency to each peak was analyzed. Compared with the EABR peaks evoked from normal cats, those of our subjects were delayed by approximately a quarter of a millisecond. It may be that such delays are due to synaptic abnormalities in the central pathways.¹⁷

In summary, we used an off-the-shelf cochlear implant to restore hearing in 5 congenitally deaf cats. Cats received behaviorally relevant auditory stimulation, which they used to gain information about their environment. The stimulation of these cats was comparable to that received by human Clarion II implant users who choose the high-resolution continuous interleaved sampling programming strategy. This experimental paradigm, combined with our previous work in describing the synapses of congenitally deaf animals, will allow us to ask significant questions about the efficacy of human cochlear implants in restoring normal synapse function in the central nervous system.

COMMENT

Several groups have examined the effects of cochlear implantation on the central nervous system.²¹⁻²³ Deafness causes a reduction in cochlear nucleus (CN) volume due to neuronal atrophy in deaf animals. Most groups found no difference between the CN ipsilateral and contralateral to the cochlear implant or in the CN

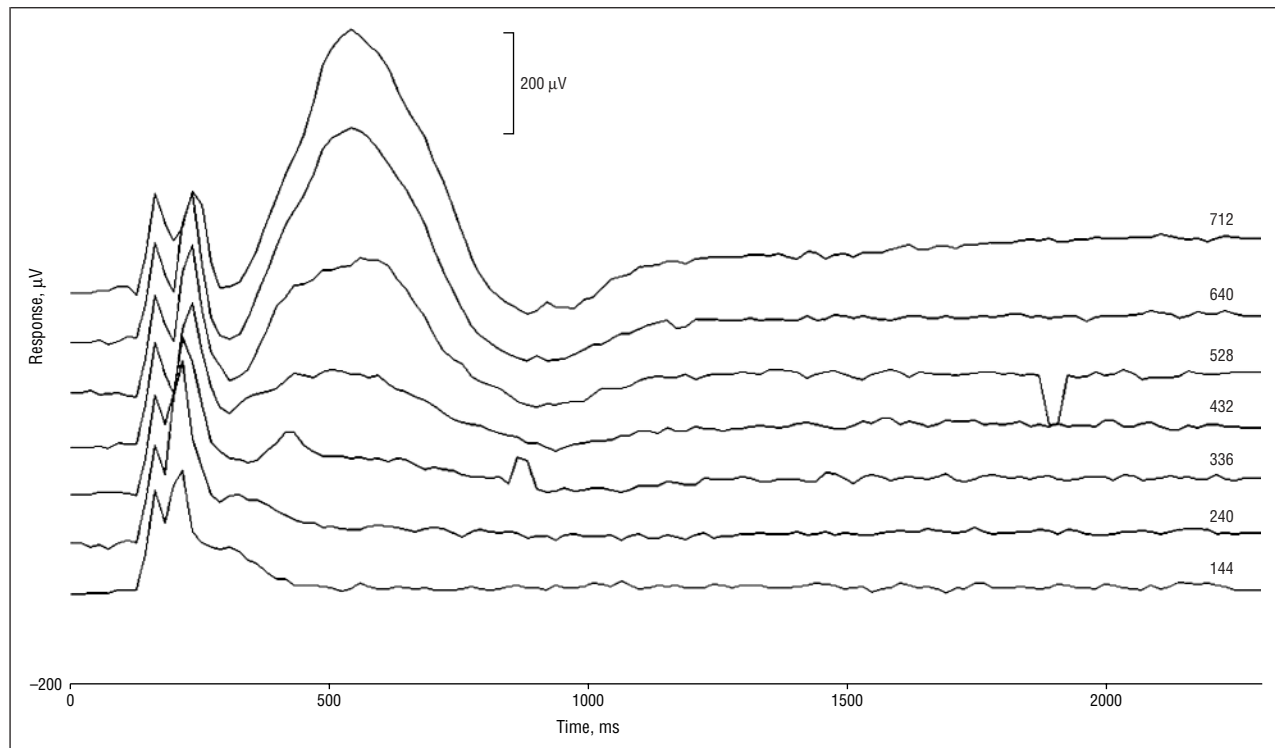


Figure 7. Neural response telemetry from a cat with a cochlear implant. Intracochlear-evoked potentials were recorded from the Clarion II device (Advanced Bionics Corporation, Sylmar, Calif). A 32-millisecond biphasic current was applied, and the changes in electrical potential at another contact on the array were averaged over 10 to 100 repetitions. A graded series of potentials evoked with increasing stimulus magnitude is shown. Note that the clipped stimulus artifact remains constant, while the peaks corresponding to neural activity in the cochlea between 200 and 800 milliseconds after stimulus onset grow with the size of the stimulus.

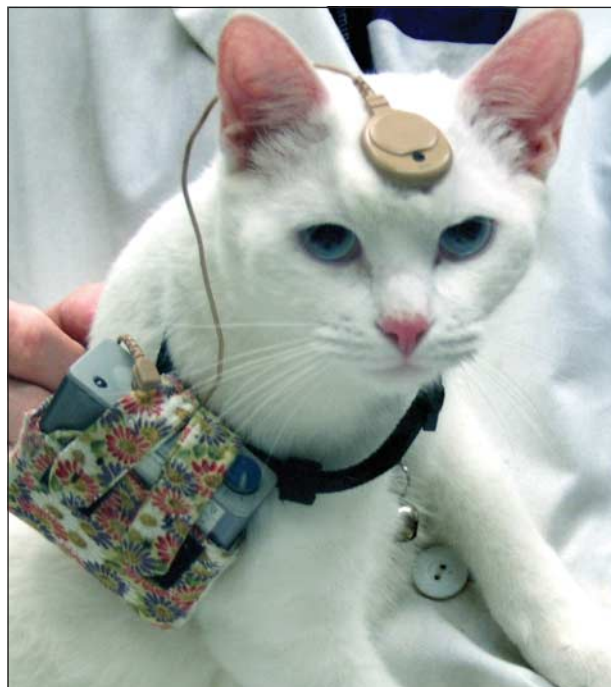


Figure 8. Photograph of a deaf white cat that has received a cochlear implant. After implantation, this cat received auditory stimulation for 7 hours a day, 5 days a week, for 3 months. After a few training sessions, it responded to a unique stimulus that signaled a food reward. The cats in this study tolerated the implant headpiece remarkably well.

of untreated deaf animals (eg, see Matsushima et al²¹). Similarly, CN volume and cell size did not change in adult patients treated with cochlear implants for adult-

onset deafness.²² However, some animal models have shown increased neuron size in the anteroventral CN ipsilateral to a cochlear implant.²³

The abnormalities observed in the endbulbs of Held in murine and feline models of profound congenital sensorineural deafness are likely to affect higher auditory structure and function. In fact, important changes have been shown in higher auditory centers due to deafness. Auditory cortex is directly involved in speech perception and language processing in humans, which makes it an appropriate place to investigate changes related to deafness and cochlear implantation. If the synaptic abnormalities observed in deaf animals persist in cats after the animals receive cochlear implants, these abnormalities may represent the structural substrate that accounts for suboptimal outcomes observed in some cochlear implant users. We are currently undertaking a quantitative analysis of these data.

Our current research will attempt to answer questions regarding the effects of electrical stimulation on the deaf auditory system. We intend to determine some of the boundary conditions for defining critical developmental periods in the auditory system and, particularly, to determine the limits of synaptic plasticity in endbulbs. Ultimately, these data could provide insight into cellular mechanisms that underlie the variable outcomes observed in people with cochlear implants. Understanding synaptic plasticity in the auditory pathway is particularly important because it might reveal how information provided by a multi-channel cochlear implant is organized to yield the effective use of spoken language.

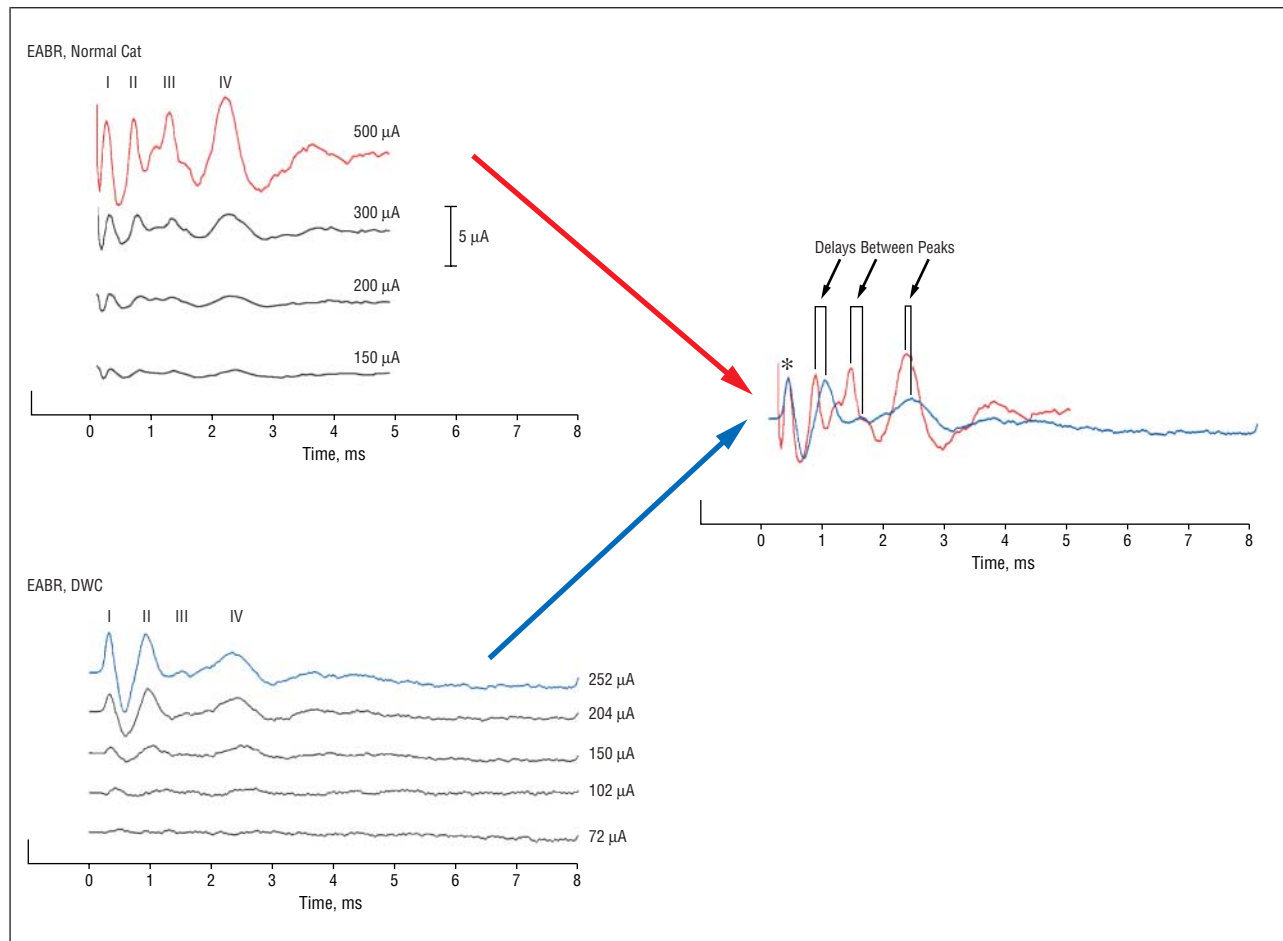


Figure 9. Electrically evoked auditory brainstem response (EABR) of a cat with a cochlear implant compared with that of a normal cat. Electrically evoked surface potentials reveal that the 5 positive peaks in the waveform of deaf white cats correspond to those found with acoustically and electrically evoked potentials in normal-hearing cats.²⁰ A 32-millisecond biphasic current pulse was applied, and the potential difference between scalp electrodes was averaged over 1000 repetitions. When the first peaks, attributed to the auditory nerve response, are aligned (shown at the asterisk), delays in the later peaks are revealed that might be due to synaptic abnormalities in the central auditory pathways.¹⁷ Reproduced with permission from Stypulkowski and van den Honert.²⁰

Submitted for publication August 28, 2003; final revision received January 6, 2004; accepted January 21, 2004.

This research was supported by National Institutes of Health grants RO1 DC00232, F31 DC005864, and T32 DC00027; The Emma Liepmann Fund, Baltimore, Md; and a gift from the Advanced Bionics Corporation.

This study was presented at the Ninth Symposium on Cochlear Implants in Children; April 24, 2003; Washington, DC.

The cochlear implants used in this study were donated by Advanced Bionics Corporation, Sylmar, Calif.

We thank Charles Finley, PhD, for help with EABRs; Charles Limb, MD, and John Niparko, MD, for help with surgery; Edward Overstreet, PhD, for help with the intracochlear-evoked potentials; Jennifer Yeagle, MEd, for guidance in device programming; and Ali Wright, BA, Conor Sheehy, BA, Karen Montey, BS, and Jenna Los, BA, for help with care of the subject cats.

Corresponding author and reprints: David K. Ryugo, PhD, Center for Hearing Sciences, Johns Hopkins University School of Medicine, 720 Rutland Ave, Baltimore, MD 21205 (e-mail: dryugo@bme.jhu.edu).

REFERENCES

1. Wiesel TN. Postnatal development of the visual cortex and the influence of environment. *Nature*. 1982;299:583-591.
2. von Noorden GK. Experimental amblyopia in monkeys: further behavioral observations and clinical correlations. *Invest Ophthalmol*. 1973;12:721-726.
3. Cochlear implants in adults and children. *NIH Consens Statement*. 1995;13:1-30.
4. Francis HW, Niparko JK. Cochlear implantation update. *Pediatr Clin North Am*. 2003;50:341-361, viii.
5. Naito Y, Hirano S, Honjo I, et al. Sound-induced activation of auditory cortices in cochlear implant users with post- and prelingual deafness demonstrated by positron emission tomography. *Acta Otolaryngol*. 1997;117:490-496.
6. Okazawa H, Naito Y, Yonekura Y, et al. Cochlear implant efficiency in pre- and postlingually deaf subjects: a study with H²¹⁵O and PET. *Brain*. 1996;119:1297-1306.
7. Fujiki N, Naito Y, Hirano S, et al. Brain activities of prelingually and postlingually deafened children using cochlear implants. *Ann Otol Rhinol Laryngol Suppl*. 2000; 185:12-14.
8. Lee DS, Lee JS, Oh SH, et al. Cross-modal plasticity and cochlear implants. *Nature*. 2001;409:149-150.
9. Giraud AL, Price CJ, Graham JM, Truy E, Frackowiak RSJ. Cross-modal plasticity underpins language recovery after cochlear implantation. *Neuron*. 2001;30: 657-663.
10. Lazeyras F, Boex C, Sigrist A, et al. Functional MRI of auditory cortex activated by multisite electrical stimulation of the cochlea. *Neuroimage*. 2002;17:1010-1017.

11. Mair IW. Hereditary deafness in the white cat. *Acta Otolaryngol Suppl.* 1973; 314:1-48.
12. Ryugo DK, Pongstaporn T, Huchton DM, Niparko JK. Ultrastructural analysis of primary endings in deaf white cats: morphologic alterations in endbulbs of Held. *J Comp Neurol.* 1997;385:230-244.
13. Klinke R, Kral A, Heid S, Tillein J, Hartmann R. Recruitment of the auditory cortex in congenitally deaf cats by long-term cochlear electrostimulation. *Science.* 1999;285:1729-1733.
14. Lorente de Nó, R. *The Primary Acoustic Nuclei.* New York, NY: Raven Press; 1981.
15. Ryugo DK, Parks TN. Primary innervation of the avian and mammalian cochlear nucleus. *Brain Res Bull.* 2003;60:435-456.
16. Kiang NYS, Watanabe T, Thomas EC, Clark LF. *Discharge Patterns of Single Fibers in the Cat's Auditory Nerve.* Cambridge, Mass: MIT Press; 1965.
17. Ryugo DK, Rosenbaum BT, Kim PJ, Niparko JK, Saada AA. Single unit recordings in the auditory nerve of congenitally deaf white cats: morphological correlates in the cochlea and cochlear nucleus. *J Comp Neurol.* 1998;397:532-548.
18. Limb CJ, Ryugo DK. Development of primary axosomatic endings in the anteroventral cochlear nucleus of mice. *J Assoc Res Otolaryngol.* 2000;1:103-119.
19. McClure RC, Dallman MJ, Garret PG. *Cat Anatomy: An Atlas, Text, and Discussion Guide.* Philadelphia, Pa: Lea & Febiger; 1973.
20. Stypulkowski PH, van den Honert C. Physiological properties of the electrically stimulated auditory nerve, I: compound action potential recordings. *Hear Res.* 1984;14:205-223.
21. Matsushima JI, Shepherd RK, Seldon HL, Xu SA, Clark GM. Electrical stimulation of the auditory nerve in deaf kittens: effects on cochlear nucleus morphology. *Hear Res.* 1991;56:133-142.
22. Chao TK, Burgess BJ, Eddington DK, Nadol JB. Morphometric changes in the cochlear nucleus in patients who had undergone cochlear implantation for bilateral profound deafness. *Hear Res.* 2002;174:196-205.
23. Lustig LR, Leake PA, Snyder RL, Rebscher SJ. Changes in the cat cochlear nucleus following neonatal deafening and chronic intracochlear electrical stimulation. *Hear Res.* 1994;74:29-37.

Papers From the AHNS 2003 Meeting

Papers From the AHNS 2003 Meeting to Be Continued in July 2004

The ARCHIVES is pleased to be publishing additional papers from the Annual Meeting of the American Head and Neck Society, Nashville, Tenn, May 2003, in the July 2004 issue. Be sure to look for these in the July issue, in addition to the AHNS papers published in the January 2004 ARCHIVES.