

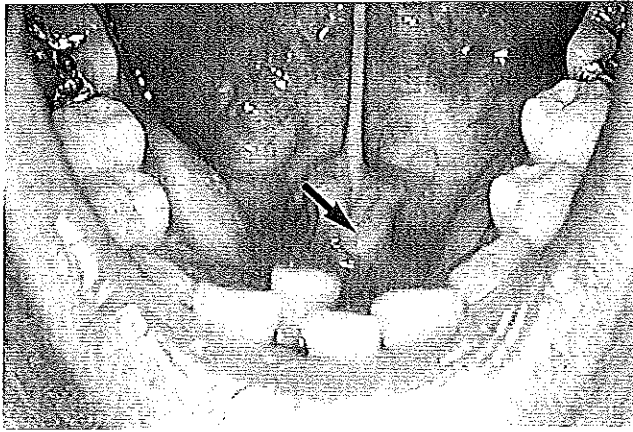Figure 61-1. The opening of Wharton's duct (arrow) adjacent to the frenulum of the tongue.

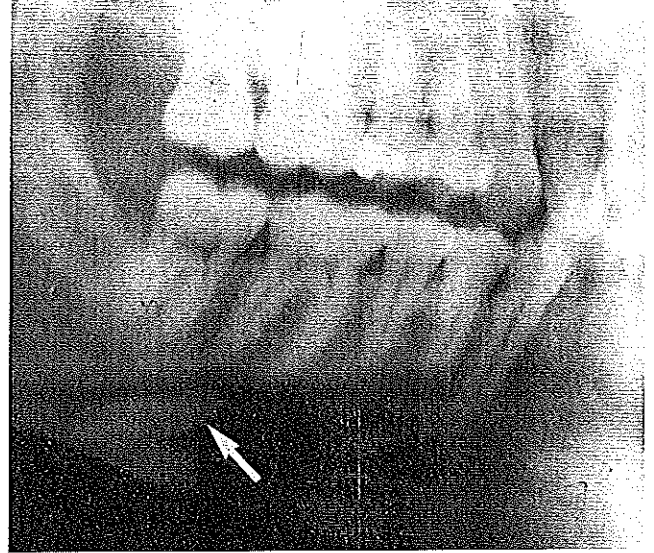


Figure 61-2. Lateral radiograph demonstrating calculus (arrow) in the hilum of the submandibular gland.

for a later date. Rarely, however, acute inflammation results in life-threatening infection because of elevation of the floor of the mouth and tongue by infectious phlegmon adjacent to the gland. In these circumstances, tracheostomy may be needed as a potentially lifesaving maneuver.

Radiographic examination should include not only a plain film of the gland itself (which can best be obtained by ordering mandible views) but also a transoral occlusal view of the floor of the mouth to detect any radiopaque calculi in the duct. Radiographic evaluation may reveal evidence of a radiopaque stone in the hilum of the gland (Fig. 61-2). Unfortunately, approximately 20% of calculi may not be radiopaque and therefore difficult to identify. Preoperative knowledge of the presence of calculi in the duct is important during excision of the submandibular gland, because failure to excise the duct up to the floor of mouth can result in retained calculi, which can later produce chronic swelling in the floor of mouth, postoperative wound infection, and untoward effects in the patient.

Computed tomography (CT) is not typically required in the evaluation of calculi unless the history is unclear or the surgeon is unsure whether the palpable mass within the gland is a potential malignancy. However, when the history is unclear or there is no history of recurring episodes of swelling, CT may provide useful information in the differentiation between gland enlargement, an isolated mass within the substance of the gland, and a mass adjacent to the gland.

A sialogram may reveal narrowing of the duct from scarring with secondary ductal ectasia within the hilum and the gland itself.

SURGICAL APPROACHES

The traditional approach to excision of the submandibular gland is via the transcervical route. Recently, intraoral excision and endoscopic excision of the submandibular gland have been described.

Transcervical Approach

Exposure is facilitated by placing a rolled blanket under the shoulders to allow the neck to be extended, thereby better exposing the submandibular triangle. The patient is then positioned with the head elevated slightly and rotated toward the opposite side. This position results in inferior displacement of the skin, platysma muscle, and subcutaneous tissue in relation to the mandible on the surgical side. As a result, the marginal mandibular nerve is found more inferiorly and is more likely to be injured by an incision directly over the gland. Therefore, the incision is made in a natural skin crease, usually slightly above the level of the hyoid bone at the inferior margin of the submandibular gland. Localization of a smaller submandibular gland can be simplified by placing a gloved finger in the mouth and depressing the floor of the mouth on the affected side.

The incision is carried through skin, subcutaneous tissue, and platysma muscle. Once through the platysma muscle, the nerve is at risk and dissection should first be directed toward the inferior portion of the submandibular gland rather than superiorly in the plane between the platysma and the submandibular gland. After exposure of the submandibular gland (often facilitated by intraoral finger palpation), the fascia overlying the gland is incised and the superior flap of fascia is elevated from the lateral surface of the gland. As this is performed, the facial vein is encountered. Ligation and elevation of this vein will help preserve the marginal mandibular nerve (Fig. 61-3). If the gland is excised as a part of a neck dissection, the nerve must be dissected free of the underlying vein and adjacent prevascular and postvascular nodes (Fig. 61-4).

When the superior aspect of the gland has been encountered, blunt dissection will free it from the surrounding soft tissue. The marginal mandibular nerve

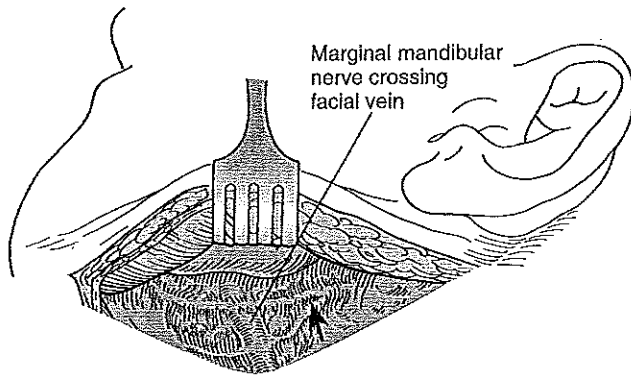


Figure 61-3. Exposure of the submandibular gland by elevating the platysmal muscle with the skin flap. Note the position of the marginal mandibular nerve (*arrow*).

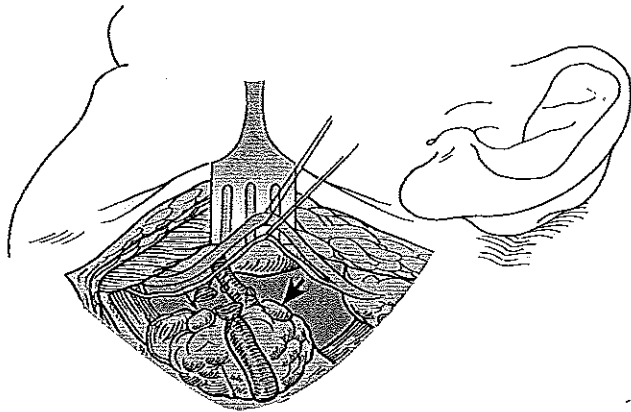


Figure 61-4. Elevation of the marginal mandibular nerve can be done by dividing the facial vein low on the gland and elevating the nerve along with the vein. Note the prevascular and postvascular lymph nodes (*arrows*).

will be preserved if dissection is maintained directly on the gland and deep to the fascia.

If the gland has been chronically inflamed and is adherent to surrounding soft tissue, the dissection may not proceed as easily as described. In these circumstances it is often necessary to identify the nerve, which generally requires the use of magnification and a nerve stimulator. Use of a facial nerve monitor with leads inserted in the depressor labialis muscle may be helpful when the clinical picture suggests that a particular case will be technically difficult.

Once the entire flap has been elevated off the lateral aspect of the gland, the anterior portion of the gland is freed from soft tissue at the level of the anterior belly of the digastric muscle. This is best done by incising the fascia over the anterior belly of the digastric muscle and reflecting it posteriorly. As this reflection occurs, the mylohyoid muscle is encountered. The muscle can be identified by the direction of its fibers extending from posterosuperior to anteroinferior (at a significantly different angle from that of the anterior belly of the digastric muscle). The dissection is carried posterior to the edge of the mylohyoid muscle. The

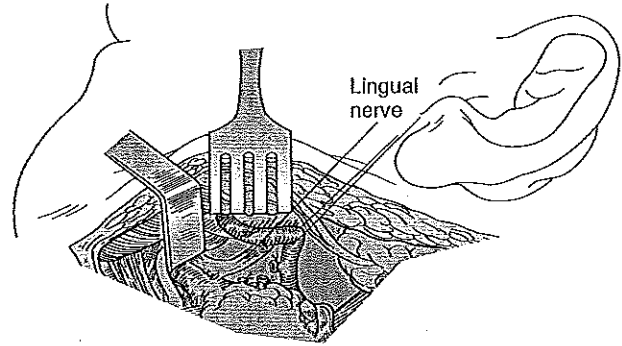


Figure 61-5. The posterior edge of the mylohyoid muscle is exposed and then retracted to expose the duct of the gland and the associated lingual nerve. In patients who have had chronic inflammation, exposure of the lingual nerve may be very difficult. The facial artery can be preserved, as demonstrated in the illustration, or divided. Division is usually easier in cases of inflammation and has no untoward effect on the patient.

mylohyoid muscle is occasionally difficult to identify, especially with chronically infected glands adherent to the muscle. This muscle may also be dehiscant in areas and lead to difficulty identifying its posterior aspect. Several perforating vessels, as well as its motor nerve, enter the mylohyoid muscle. The vessels must usually be sacrificed to free the overlying portion of the submandibular gland. As the gland is retracted posteriorly, the posterior aspect of the mylohyoid muscle is encountered. A small right-angled retractor can be used to retract the muscle anteriorly off the deep portion of the gland (Fig. 61-5). This retraction is usually easy except in chronically inflamed cases with marked fibrosis. In such cases, sharp dissection may be required to free the mylohyoid muscle from the gland and its surrounding soft tissue.

The anterior portion of the gland, the duct with the closely adherent sublingual gland, and the lingual nerve will be encountered immediately deep to the mylohyoid muscle. The lingual nerve can be seen superiorly as a broad band extending from deep to the mandible posteriorly and looping close to the anterior portion of the gland, where it gives rise to nerve roots extending into the submandibular ganglion. The nerve ascends superiorly as it extends anteriorly to innervate the anterior aspect of the tongue and floor of the mouth. This nerve must be carefully dissected free and the rootlets incised. Every effort should be made to identify and preserve the lingual nerve, because injury will result in loss of sensation of the lateral aspect of the oral tongue. In patients with significant scarring secondary to chronic inflammatory disease, this dissection may be difficult and tedious.

After the nerve has been identified and the rootlets incised, the duct can usually be identified in the fascial planes superficial to the floor of the submandibular triangle. A large vein generally accompanies the duct and should be ligated separately.

The hypoglossal nerve can then be seen extending along the floor of the triangle, where it emerges from deep to the posterior belly of the digastric muscle. Care

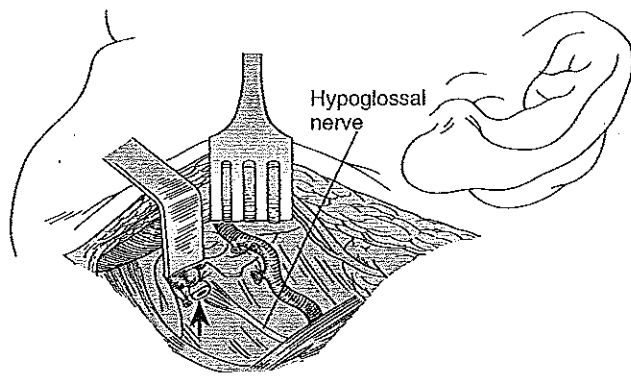


Figure 61-6. The branches of the lingual nerve passing to the submandibular ganglion are divided to free the nerve from the specimen. The duct is divided (arrow) and the specimen is removed. Care must be taken to ensure that there are no calculi distal in the duct, or postoperative infection in the duct remnant will result.

must be taken to avoid injury to the hypoglossal nerve as it courses along the floor of the submandibular triangle. Injury is unusual unless previous inflammation has made it difficult to identify the plane deep to the gland.

Once the hypoglossal nerve has been identified, the duct can be divided (Fig. 61-6). Care must be taken to include dissection of the duct up to the mucosa of the floor of the mouth; otherwise, stones can be retained in the duct and result in postoperative chronic inflammatory disease of the duct remnant. Bimanual palpation at this stage often helps prevent retained stones in the duct.

When the anterior portion of the gland has been freed from the lingual nerve and submandibular duct, the remainder of gland is easily detached from the underlying fascial planes over the floor of the submandibular triangle. The gland can then be retracted inferiorly with countertraction placed on the soft tissue superior to the gland, and the superior aspect of the gland is dissected free from the soft tissue just inferior to the mandible. Care must be taken to avoid injury to the marginal mandibular nerve because it courses just lateral and superior to the gland. Injury is avoided by either identifying the nerve or maintaining dissection within a plane immediately adjacent to the substance of the gland. Although the latter technique is relatively simple in most cases, in a severely inflamed gland, dissection may be difficult and bleeding persistent; the surgeon must identify the nerve under magnification to avoid injuring it.

As the gland is reflected inferiorly, the facial artery can be seen indenting the posterosuperior surface of the gland. It is usually divided as it leaves the gland superiorly and then again as it enters the gland inferiorly. It is possible, however, to preserve the artery in noninflamed cases by dissecting the artery free of the gland and individually identifying, dividing, and ligating the feeding vessels extending into the gland proper. When the gland has been freed from the artery by either dissection or transection, the gland is removed.

Once the gland has been removed, the submandibular triangle should be examined for vessels that require ligation. Particular care should be taken to examine the anterior portion of the triangle deep to the mylohyoid muscle to rule out potential bleeding vessels. The wound is irrigated, a Hemovac suction drain is inserted, and the wound is closed in layers beginning with the platysma muscle and followed by subcutaneous closure and then a cuticular closure that approximates the skin in a cosmetically acceptable manner.

An alternative technique is to expose the duct and lingual duct and ligate the facial artery posteriorly as it enters the submandibular triangle from deep to the posterior belly of the digastric muscle. The submandibular gland can then be pedicled on the lingual nerve and Wharton's duct, and the gland is excised. This technique allows better exposure of the lingual nerve and Wharton's duct during dissection of these structures.

Intraoral Approach

An alternative surgical approach to the submandibular gland is the intraoral approach. This procedure has the potential to circumvent the two most common untoward sequelae of the transcervical approach, namely, scarring from the cervical incision and the risk of injury to the marginal mandibular branch of the facial nerve. Intraoral excision of the submandibular gland requires nasotracheal intubation followed by injection of lidocaine with epinephrine (1:100,000) into the mucosa for hemostasis. Adequate lighting, preferably with a fiberoptic headlight, is essential. After insertion of a probe into the orifice of Wharton's duct, the intraoral incision is made through the mucosa of the floor of the mouth from the duct orifice posteriorly to the lingual aspect of the retromolar region.² Dissection and removal of the sublingual gland will facilitate exposure of the duct.³ Careful dissection along the course of Wharton's duct will reveal its close relationship to the lingual nerve. Retraction of the tongue and floor of the mouth, including the lingual nerve, allows visualization of the mylohyoid muscle.² Anterior retraction of the posterior margin of the mylohyoid muscle allows visualization of the superficial portion of the submandibular gland. Blunt dissection is used to free the submandibular gland from surrounding structures. Transcervical pressure on the gland will elevate the gland in the floor of mouth and aid in visualization. The facial artery and vein and their branches are identified and may be either avoided or ligated. The gland is then carefully removed and hemostasis is achieved. A drain may be inserted through the incision site, and the mucosa is reapproximated with absorbable suture.

The intraoral approach appears to achieve its goals of obviating the need for a transcervical incision and minimizing risk to branches of the facial nerve. The marginal mandibular nerve is the most frequently injured nerve in the traditional transcervical approach, with reported injury rates ranging from 1% to 7%.³

Branches of the facial nerve are not at risk with the intraoral approach, so they are not identified during this dissection. Pitfalls of the intraoral approach, however, stem from significant retraction of the floor of the mouth, including the lingual nerve and mylohyoid muscle, which is necessary for adequate exposure of the gland. In one study, temporary injury to the lingual nerve was observed in almost all patients, and 68% reported a temporary decrease in tongue mobility that resolved within 2 weeks of surgery and was attributed to edema of the floor of the mouth rather than injury to the hypoglossal nerve.²

Endoscopic Approach

Two methods for endoscopic resection of the submandibular gland have recently been proposed. The first is a modification of the intraoral approach in which the incision and technique are virtually identical to that just described. An endoscope is introduced through an intraoral incision for visualization of the surgical field by lighting and magnification.⁴

The second technique entails a modified transcervical approach for endoscopic excision of the submandibular gland. To date, it has been reported only in a cadaver model. A single 14-mm and two 5-mm incisions placed in the inferior aspect of the neck provide entry for the instruments. Subcutaneous dissection is performed with a 1000-mL hernia balloon inflated to 500 to 700 mL. The balloon is then removed and carbon dioxide is insufflated to a pressure of 4 mm Hg to maintain the operating field. The submandibular gland is identified with the endoscope and endoscopic dissection tools, and the dissection is performed much as in the traditional transcervical approach. Not surprisingly, the authors reported subcutaneous emphysema in two of six of their specimens.⁵ We have no personal experience with this technique, but nonetheless, the endoscopic approach will no doubt undergo further study.

POSTOPERATIVE MANAGEMENT

Postoperative management is minimal and includes elevation of the head of the bed and removal of the drain after 24 to 48 hours. Excessive persistent drainage will require re-exploration, because uncontrolled hematoma in this area may result in airway difficulty secondary to displacement of the tongue musculature. Patients undergoing excision of the submandibular gland are customarily observed for 24 hours postoperatively, primarily to avoid the risk of airway compromise because of unanticipated postoperative swelling.

PEARLS

- The marginal mandibular nerve should be identified and protected by dissecting along the lateral surface of the gland. Facial nerve monitoring with a handheld nerve stimulator is helpful in difficult cases, especially in patients with a long history of chronic inflammatory disease.

- When the gland is removed in conjunction with radical neck dissection, the nerve must be identified to avoid injury posterior to the gland, where it may often dip a significant distance below the level of the mandible.
- Routine identification of the nerve in neck dissection is also necessary for removal of the prevascular and postvascular nodes. These nodes require removal, particularly with lesions involving the lateral oral cavity, alveolus, and sinus.
- Incomplete removal of submandibular duct calculi can be managed in the postoperative period by probing the duct intraorally and removing the stone via an intraoral route. It is highly desirable to remove the calculus at the time of excision of the submandibular gland.
- The proximal stump of the facial artery should be double-ligated and the wound examined for bleeding vessels before closure.
- Care must be taken in patients who have had significant infection and scarring to ensure identification of the lingual nerve before sectioning the duct.
- Care should be taken after the gland is free posteriorly to visualize the hypoglossal nerve as it courses deep to the vessels, parallel to the submandibular duct. If inflammation hinders identification of the nerve, it is advisable to find the nerve inferior to the posterior belly of the digastric muscle and follow it in a posterior-to-anterior direction through the submandibular triangle to avoid injury.

PITFALLS

- The marginal mandibular nerve can be injured and result in paralysis of the lower lip, especially in patients with chronic inflammation.
- Interruption of the smaller accessory nerves that loop inferiorly over the lateral surface of the gland is less significant than injury to the main branch of the marginal mandibular nerve, which usually courses immediately superior to the gland overlying the prevascular and postvascular nodes.
- Failure to dissect Wharton's duct all the way to the mucosa of the floor of the mouth during excision of the submandibular gland can result in retained calculus later on.
- Postoperative hemorrhage can lead to significant airway obstruction as a result of swelling of the tongue musculature.
- The lingual nerve can be injured by injudicious sectioning of the duct without first identifying and freeing the nerve where it lies directly superior to the duct.
- The hypoglossal nerve may be adherent to the medial aspect of the gland and inadvertently resected.