

# JOHNS HOPKINS Gynecology & Obstetrics

WINTER 2017



NEWS FROM THE JOHNS HOPKINS  
DEPARTMENT OF GYNECOLOGY AND OBSTETRICS

## MATERNAL-FETAL MEDICINE

# A Team Approach to Twin Anemia Polycythemia Sequence

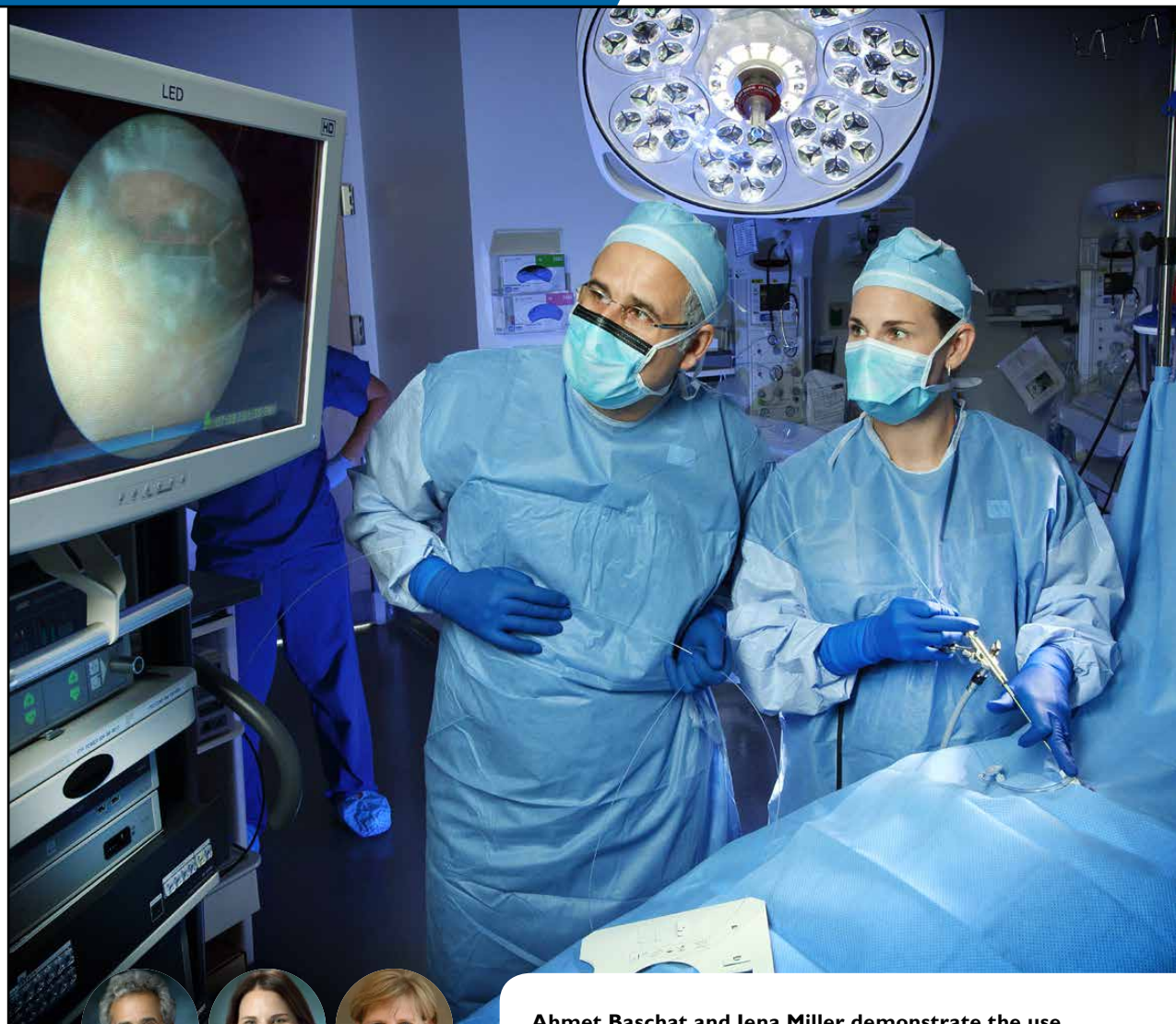**T**HE 37-YEAR-OLD PATIENT HAD ALREADY given birth to a set of fraternal twin boys after an in vitro fertilization procedure 3 years ago. But she and her husband wanted just one more child, so they underwent a single embryo transfer. At the initial ultrasound, they received shocking news—not one, but three embryos appeared brightly on the screen, identical triplets sharing a single placenta.

Such monochorionic pregnancies not only have the risks that come with any multiple gestation, such as a higher chance of premature birth, gestational diabetes, pre-eclampsia and anemia, but also their own specific risks, including problems that result from having a commingled blood supply on the placenta, such as twin-to-twin transfusion syndrome.

Aware of some of these risks after their earlier twins, the couple contacted the Johns Hopkins Multiple Gestation Clinic, says clinic director and maternal-fetal medicine specialist **Linda Szymanski**. “They were initially interested in reducing the pregnancy,” she explains.

With the clinic’s close relationship with the Johns Hopkins Center for Fetal Therapy, Szymanski arranged for the couple to be seen at nine weeks gestation by fetal therapy colleagues **Ahmet Baschat** and **Jena Miller**. After performing another ultrasound to evaluate the fetuses’ orientations, sizes and connections to the placenta, the team recommended that the patient continue the pregnancy. “A reduction would require an invasive procedure unique to monochorionic multiples that could be dangerous to the whole pregnancy,” says Miller. “We all decided to keep a close eye out for any complication that might arise.”

Every two weeks, the patient came for regular prenatal care appointments at Johns Hopkins, seeing either maternal-fetal medicine or fetal therapy specialists—or sometimes both—at each visit. “That way, we could screen, monitor and treat any complications that arose at the same time with the expertise of both groups,” Baschat says. “That type of comprehensive care exists at



**Ahmet Baschat and Jena Miller demonstrate the use of a fetoscope for fetal laser surgery. Inset left to right: Ahmet Baschat, Jena Miller and Linda Szymanski.**

**AT 26 WEEKS, THE FETUSES HAD A REASONABLE CHANCE OF VIABILITY OUTSIDE THE WOMB, BUT THEY WERE ALSO VULNERABLE TO COMPLICATIONS THAT CAN ARISE FROM PREMATURITY.**

few centers anywhere in the world.”

The pregnancy proceeded smoothly until 23 weeks, when the patient contracted influenza, which landed her in the hospital for a few days, but eventually had a full recovery. But then, at 26 weeks, her care team noticed a few abnormal findings on an ultrasound that had the potential to be more serious and long lasting. One fetus’ sac had started to expand, showing an increase in amniotic fluid that suggested increasing blood volume. Eventually, through Doppler that tracked blood flow, the doctors diagnosed the fetuses with twin anemia polycythemia sequence (TAPS), a form of twin-to-twin transfusion syndrome. TAPS occurs when small caliber arteriovenous anastomoses join, allowing unequal blood flow among fetuses.

At 26 weeks, the fetuses had a reasonable chance of viability outside the womb, but they were also vulnerable to complications that can arise from prematurity. The only treatment for TAPS is fetal laser surgery to close off and separate the blood vessels—a potentially

*(Continued on back page)*



Dear Colleagues,

The Department of Gynecology and Obstetrics is experiencing tremendous growth across the tripartite mission. Highlighted in this issue is but a small sample of our innovative clinical, research and education programs.

Karen Wang, Kristin Patzkowsky and Khara Simpson offer minimally invasive gynecologic surgical options for many patients with conditions previously requiring extensive open surgery. A newly accredited post-graduate minimally invasive gynecologic surgical training program will begin in July of 2017.

Amanda Fader and Ed Tanner continue to lead gynecologic oncology in minimally invasive options for the treatment of cancers. Ie-Ming Shih and Jim Segars direct our Richard W. TeLinde Gynecologic Pathology Research Program and our Howard W. and Georgeanna Seegar Jones Laboratory of Reproductive Sciences, respectively. These programs focus on translational research in gynecologic cancers, fibroids and endometriosis.

Arthur Vaught joins our Division of Maternal-Fetal Medicine, bringing additional expertise in critical care medicine. Our department continues to push the limits of discovery and innovation as they apply to patient care and research.

I hope you enjoy reading about some of our team members in this issue. For a broader look at our department and programs, please visit us at [hopkinsmedicine.org/gynecology\\_obstetrics](http://hopkinsmedicine.org/gynecology_obstetrics).

Andrew J. Satin M.D.  
Director  
Johns Hopkins Department of  
Gynecology and Obstetrics

## GYNECOLOGIC SURGERY

# Minimally Invasive Surgery Options for Gynecologic Surgeries

**T**HE FIRST TOTAL LAPAROSCOPIC hysterectomy was performed in 1989. However, as minimally invasive surgery grew in other fields, it lagged for gynecology. It wasn't until the past decade or so that doctors and patients alike have begun to take advantage of the spectrum of benefits that these procedures provide, say **Kristin Patzkowsky** and **Karen Wang**, both members of the Minimally Invasive Surgery Group in the Department of Gynecology and Obstetrics at Johns Hopkins. **Khara Simpson**—who, like Patzkowsky and Wang, is fellowship-trained in minimally invasive gynecologic surgery—recently joined the team in September.

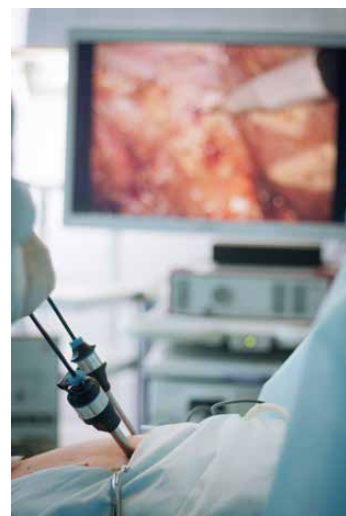Much like minimally invasive surgery in other fields, using these techniques can provide a lower risk of complications during procedures, such as bleeding, and an easier recovery, with less pain and bleeding afterward, a lower risk of infection, and an earlier return to normal function. “For many of our patients, who juggle busy home and work lives,” says Wang, “being able to return to a normal schedule as soon

as possible is especially attractive.”

The three surgeons perform all of their procedures laparoscopically, even those that can be a challenge to perform as open procedures, including myomectomies for large or numerous fibroids, resections for stage 3 or 4 endometriosis, or total hysterectomies for large fibroid uteri. Any of these cases can be performed either as traditional laparoscopies or robotically, depending on surgeon preference, Wang says.

The team performs hundreds of minimally invasive gynecologic surgeries each year.

For patients interested in avoiding transfusions for religious or other reasons, Wang adds, their minimally invasive group offers a “bloodless medicine service,” with blood salvaged,



**Hundreds of minimally invasive gynecologic surgeries are performed each year at Johns Hopkins.**

filtered and returned to patients if needed.

The team plans to establish a multidisciplinary endometriosis group that can tackle this often complicated disease from multiple angles, including with medicine, surgery, radiotherapy, nutrition, physical therapy, pain therapy and reproductive endocrinology for patients interested in preserving their fertility. They also plan on establishing a minimally invasive gynecologic surgery fellowship to train future generations of surgeons in

these techniques.

“Many of our patients tell us that if they'd known how easy the surgery would be, they would have done it years ago,” says Patzkowsky. “That's why we do what we do: to help people get back to the lives they deserve.” ■

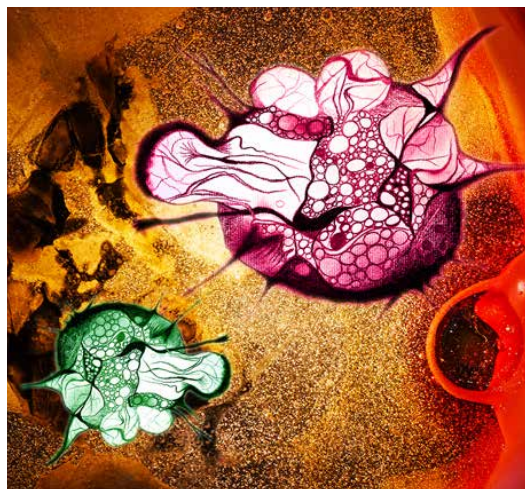## RESEARCH UPDATE

### Gynecologic Pathology Research Update

Directed by **Ie-Ming Shih**, the Richard W. TeLinde Gynecologic Pathology Research Program focuses on ovarian, uterine and cervical cancers, as well as gestational trophoblastic diseases and endometriosis.

Interdepartmental faculty members collaborate with researchers in the Howard W. and Georgeanna Seegar Jones Laboratory of Reproductive Sciences and Women's Health Research to study the molecular pathogenesis and translational aspects of endometriosis, a disease that affects many women of childbearing age.

The team has applied next-generation sequencing and other state-of-the-art technologies to explore the origin, clonal evolution and mechanisms of the metastatic nature of endometriosis. Research-




**Endometrial cells migrate from the uterus to abdominal cavity and tissue to form endometriosis. Artist's rendition by Ie-Ming Shih.**

ers are assessing new biomarkers and developing new methods for early detection and risk prediction. Investigators are also studying the molecular mechanisms behind how some endometriosis cases develop into endometriosis-related ovarian cancers. ■

### Advances in Ovarian Cancer Research

Johns Hopkins scientists are developing new tools to identify and characterize molecular alterations that occur during the formation and progression of ovarian cancers. Recent genomewide analyses have pinpointed specific molecular changes in several new cancer-associated genes, including ARID1A, Rsf-1, SYK, NAC-1 and Notch3. Translational research focuses on early cancer detection using body fluid samples from liquid biopsies and innovative molecular techniques. Researchers are also studying new therapeutic reagents and immunotherapies that target cancer-associated molecules, with the goal of developing new drugs to treat recurrent ovarian cancer. ■

**A 3-D view of ovarian cancer cells (dark staining). Artist's rendition by Ie-Ming Shih.**



[Learn more: gynecologycancer.org](http://gynecologycancer.org)

# Immunotherapy Trial Shows Promise Fighting Endometrial Cancer

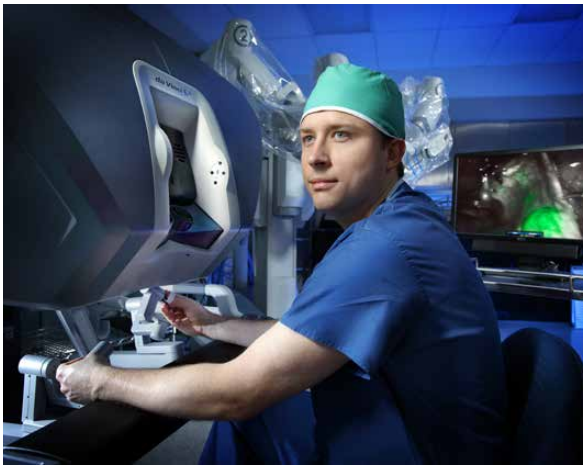**F**OR MANY GYNECOLOGIC CANCERS, THE traditional therapies—surgery, chemotherapy and radiation—offer only a temporary fix. When the disease recurs after each round of treatment, patients eventually run out of options.

Part of the reason gynecologic and many cancers are so difficult to treat is their inherent skill in evading the immune system. While helper T cells and other components of a healthy immune system work together to identify and eliminate many other types of dangerous and deadly cells by probing their surfaces for foreign proteins, cancer cells have the ability to cloak themselves in proteins displayed by healthy cells—a type of “identify theft” that keeps them hidden from immune discovery and destruction.

However, says **Amanda Fader**, director of the Johns Hopkins Kelly Gynecologic Oncology Service, a new type of immunotherapy offers patients a potentially effective weapon in the cancer battle that could give them a chance for prolonged remission or even eradicate some cancers completely.

“Immunotherapy has been one of the most exciting breakthroughs in cancer care that we’ve seen in decades. Impressive responses have been observed in patients with melanoma, lung, colorectal, and now, gynecologic cancers,” Fader says.

Recently, Fader and her Johns Hopkins gynecologic oncology colleague **Edward Tanner** experienced this firsthand in a phase II clinical trial at Johns Hopkins on which they served as co-investigators with **Dung Le** and **Luis Diaz** from the Johns Hopkins



**Tumors that are hypermutated may have the best responses to checkpoint inhibitor therapy, says Edward Tanner, associate director, F.J. Montz Fellowship in Gynecologic Oncology**

Kimmel Cancer Center. The trial tested the effectiveness of pembrolizumab, or anti-PD-1, a monoclonal antibody that’s a checkpoint inhibitor, a relatively new class of immunotherapy that allows helper T cells to recognize cancer cells.

Administered intravenously, pembrolizumab allows the immune system to identify and destroy cancer cells. Although the trial included just 10 women with recurrent endometrial cancer, all of whom had already undergone multiple traditional



**Amanda Fader, director of the Johns Hopkins Kelly Gynecologic Oncology Service, presented the findings from this trial as a late-breaking abstract at the 2016 Society of Gynecologic Oncology Annual Meeting on Women’s Cancers in March.**

lines of treatment, the results in this small pool were exciting, says Tanner. Seven of the patients responded positively, with endometrial tumors either dramatically shrinking or disappearing completely, and one patient’s disease stopped progressing.

“This type of response rate is very promising,” Tanner explains. “At most, we’d expect to see only about a quarter of patients with recurrent endometrial cancer respond to chemotherapy in this setting. And tumors that are hypermutated may have the best responses to checkpoint inhibitor therapy.”

Fader, who will lead a new trial investigating this therapy in a larger number of patients, says that checkpoint inhibitors and other immunotherapies could eventually be the treatments that turn the corner for many patients in the fight against cancer. ■

## CRITICAL CARE

# Septic Shock After Routine Birth Leads to Total Abdominal Hysterectomy

**I**T WAS A RELATIVELY UNREMARKABLE PREGNANCY, labor and delivery for the 36-year-old first-time mother. Induced after she went past her due date, she gave birth to a healthy baby boy at her local community hospital without an epidural on March 18, 2016. The only immediate consequence was a third-degree tear, not uncommon for a first birth.

But, within a day of delivery, this routine birth slowly took a turn for the worse. The patient began complaining of intense abdominal pain and profuse diarrhea. She developed a fever, and her blood pressure began to drop lower and lower. Transferred to her hospital’s ICU, she was given fluids and an antibiotic, then two, then three, but she still developed septic shock. Although her blood cultures showed clear signs of infection, a pelvic exam, CT scan and ultrasound showed no obvious source. As her life-threatening complications grew worse, the patient, her family and her doctors made the decision to transfer her to Johns Hopkins, says **Arthur Vaught**, a subspecialist in both critical care and maternal-fetal medicine at The Johns Hopkins Hospital.

To save their new patient, Vaught and his colleagues knew it would be critically

important to identify the source of the infection. Enlisting colleagues in gynecologic oncology, who often assist in complex cases that involve complicated wounds or necessitate surgery, the doctors carefully removed the third-degree laceration sutures. There, they found black, necrotic tissue. The patient was soon in the operating room for a tissue debridement of that infected tear. While she was sedated, the team also performed an endometrial biopsy.

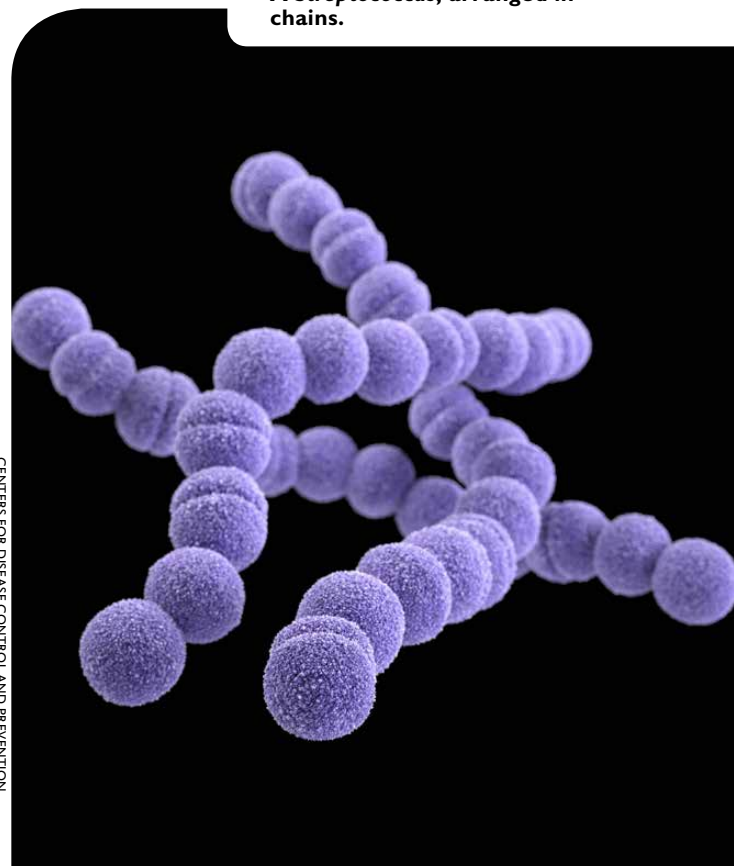
Although the patient’s condition improved after this procedure—reducing her need for vasopressor therapy—blood tests and her persistent tachycardia showed that the infection remained. “It was clear that we didn’t have source control,” Vaught remembers.

Soon, results of the endometrial biopsy returned positive for group A *Streptococcus*, suggesting that this relatively uncommon infection continued unabated in her uterus. Vaught and his colleagues knew that the likely cure was a hysterectomy, but the decision to move ahead was fraught. “It’s an especially grave move  
*(Continued on back page)*



**Arthur Vaught**

**A three-dimensional, computer-generated image of a group of erythromycin-resistant group A *Streptococcus*, arranged in chains.**



CENTERS FOR DISEASE CONTROL AND PREVENTION

## A Team Approach

(continued from page 1)

risky proposition for a triplet pregnancy. “Making the right decision was agonizing for the entire team, the patient and her family,” Szymanski says.

In the end, however, the consensus was to move ahead, with Baschat and Miller performing the surgery. As the fetuses recovered in the days afterward, repeated ultrasounds showed that it was a success. Blood volume among the triplets gradually normalized. At 34 weeks, on the same birthday as their older twin siblings, the babies—three boys—were delivered jointly by Szymanski and Miller, born healthy, with nearly identical weights and blood counts.

“At every turn, the patient and her family knew that they had an entire team caring for them,” Szymanski says. “It’s the kind of care we strive to deliver to every patient who comes through our doors.” ■

## Septic Shock After Routine Birth

(continued from page 3)

to remove the uterus of a young woman who has previously been healthy and take away her ability to carry future children,” Vaught says. “We all felt a heavy burden in trying to decide if this was really the right thing to do.”

After extensive meetings with members from gynecologic oncology, critical care and infectious diseases specialists, and counseling the patient’s family, Vaught and his colleagues moved forward with a total abdominal hysterectomy. As they made their initial incisions and entered the peritoneal cavity, it was clear that they’d made the right choice, he recalls. Abundant infectious fluid spilled out of the patient’s abdomen, and necrotic tissue filled her uterus. Her condition steadily improved after surgery, and within 10 days, she was able to leave the hospital to enjoy her new baby.

“When a young mother is critically ill, it hits home for everyone,” says Vaught, who treats patients with a variety of emergent obstetric conditions, including HELLP syndrome, postpartum hemorrhage, peripartum cardiomyopathy and others. “It is a privilege to work with a medical faculty and staff dedicated to caring for sick, pregnant women. We all feel a sense of both accomplishment and humility when we are able to successfully bring a woman out of her critical illness and reunite her with her baby, family and community.” ■

## Explore Our Online Resource for Physicians: Clinical Connection

Connect with Johns Hopkins health care professionals sharing insights on the latest clinical innovations and advances in patient care.

Scan the QR code or visit [www.hopkinsmedicine.org/clinicalconnection](http://www.hopkinsmedicine.org/clinicalconnection)

While you’re there, sign up for the Clinical Connection e-newsletter.



# JOHNS HOPKINS Gynecology & Obstetrics

This newsletter is published for the Johns Hopkins Department of Gynecology and Obstetrics by Johns Hopkins Medicine Marketing and Communications.

901 South Bond St. / Suite 550  
Baltimore, MD 21231

### Department of Gynecology and Obstetrics

Andrew J. Satin, M.D., director

### Marketing and Communications

Dalal Haldeman, Ph.D., M.B.A.  
Senior Vice President, Marketing and Communications

Christen Brownlee, writer

Michael Keating, managing editor

Max Boam, designer

Keith Weller, photographer

For questions or comments, contact:  
[mkeating@jhmi.edu](mailto:mkeating@jhmi.edu) or 410-614-1366

© 2016 The Johns Hopkins University and  
The Johns Hopkins Health System Corporation.

For more information or to refer  
a patient, call 443-997-0400

Non-Profit Org.  
U.S. Postage  
PAID  
Permit No. 5415  
Baltimore, MD

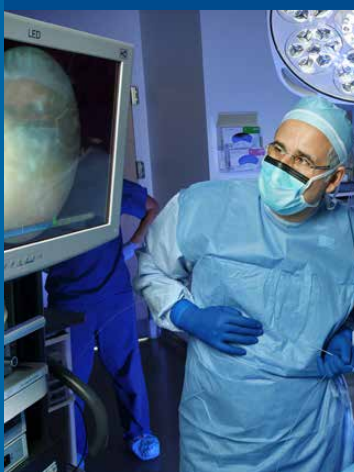# JOHNS HOPKINS Gynecology & Obstetrics

WINTER 2017



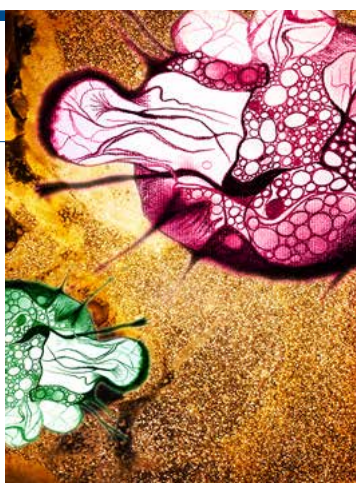NEWS FROM THE JOHNS HOPKINS DEPARTMENT OF GYNECOLOGY AND OBSTETRICS

Inside



1

A Team Approach to Twin Anemia Polycythemia Sequence



2

• Research Update  
• Minimally Invasive Surgery



3

• Septic Shock After Routine Birth Leads to Total Abdominal Hysterectomy  
• Immunotherapy Clinical Trial